PREFACE

Information presented in this report is interim documentation of a 1992 environmental evaluation of livers from common loons collected throughout the Northeast United States (PACF Catalog Number 5030009, Regional ID Number 5F04). The evaluation was undertaken to correlate specific lead levels, toxicity, and fishing sinker presence with loon mortality. This evaluation represents a cooperative effort between Tufts University School of Veterinary Medicine (TUSVM) and the U.S. Fish and Wildlife Service. The Principal Investigators are Cyndi Perry (USFWS) and Mark Pokras (TUSVM). This report was prepared jointly by the Fish and Wildlife Service and TUSVM.

Questions, comments, and suggestions related to this report are encouraged. Written inquires should refer to report Number RY92-NEFO-2-EC and be directed to the following address:

U.S. Fish and Wildlife Service
New England Field Office
22 Bridge Street, Suite 400
Concord, NH 03301-4901

The Cooperators request that no part of this report be taken out of context, and if reproduced, the document should appear in it entirety.

The use of trade names in this report is solely for identification purposes and does not constitute an endorsement by the U. S. Government or TUSVM.

ABSTRACT

From 1989-1992, 124 loons found dead or moribund throughout the Northeast United States were examined by personnel from Tuft University School of Veterinary Medicine. Major pathological findings included 30 birds dying of trauma; while 29 deaths were found to have parasitic infection, 28 adult birds had ingested metal (27 with fishing sinkers and one with buckshot), 19 birds were diagnosed with aspergillosis, and 5 chicks with omphalitis (an umbilical infection). Ingested metal (primarily fishing sinkers) was found in 67.5 % of the adult loons from freshwater lakes. Toxicological data (liver tissue analysis) from a subset of 38 individuals found that lead, mercury, aluminum, selenium, and cadmium concentrations were elevated in the Northeast United States loon population. In adults, liver lead concentration ranged from < 0.05 to 22.60 ppm. In most cases metal ingestion was accompanied by elevated lead liver levels. Results of this study confirm that much of the summer loon mortality is closely linked to anthropogenic activities on and near their breeding lakes.

INTRODUCTION

Populations of common loons (*Gavia immer*) are of special concern in much of North America because of increased encroachment by anthropogenic activities on and around their breeding lakes, as well as northward shifting breeding boundaries and an apparent overall declining loon population (McIntyre 1988). This migratory species has a summer breeding range on inland lakes along the northern United States from Maine to Minnesota and throughout Canada. Many of these birds winter along the length of the Atlantic coast and the Gulf of Mexico. The common loon has been designated as either an endangered (VT) or threatened (NH) species, or species of special concern (MA and NY) in many Northeastern States.

Loons are also a species of interest because of their position within the food web. The loon is a top predator in aquatic food webs and may serve as an indicator species for the aquatic environment. Although the reproductive biology of loons is relatively well known, only a few studies exist regarding contaminant-related loon mortality (Ream 1976, Haseltine et al. 1983, Belant and Anderson 1990). This study begins to address the causes of loon morbidity and mortality in the Northeast United States.

Adverse impacts to wildlife from lead shot ingestion, particularly waterfowl has been well documented (Longcore et al. 1974, Kraft 1984, Sanderson and Bellrose 1986, Friend 1987). However, reports from Europe have shown waterfowl mortality due primarily to the ingestion of lead fishing sinkers (Erne and Borg 1969, Borkenhagen 1979, Goode 1981). The mute swan (*Cygnus olor*) population has been declining in parts of England over the last 25 years predominately due to the ingestion of lead fishing sinkers(Goode 1981). Both lethal (Birkhead 1982) and sublethal (i.e., lowered reproductive success; Birkhead 1983) effects have been shown to occur in mute swans. Several recent studies in the United States have found evidence of lead toxicosis in waterfowl apparently due to the ingestion of lead fishing sinkers (Blus et al. 1989, Pokras and Chafel 1992, Poppenga 1992).

STUDY OBJECTIVES

The primary objectives of this cooperative study are to:

-Identify those individuals who appear (through radiographs) to have ingested lead fishing sinkers.

-Perform analysis for lead and other metals which are potential contaminants of concern (e.g. mercury) on liver tissue of those individuals who appear to have ingested sinkers as well as several individuals who have not (background levels).

-Determine the relationship between loon liver lead levels and sinker ingestion.

-Identify any other contaminants of concern that may have influenced the health of the individuals.

METHODS

Collection

Loons found dead or moribund throughout the Northeast United States were collected primarily by the U.S. Fish and Wildlife Service, Maine Audubon Society and the Loon Preservation Committee of New Hampshire. Private citizens, wildlife rehabilators and area veterinarians also contributed birds. Loons were collected from freshwater lakes in Maine, Massachusetts, New Hampshire, New York, and Vermont. Birds were also collected from the coastal shorelines in Connecticut, Maine, Massachusetts, and Rhode Island. Birds were packed on ice, sent by overnight delivery, and necropsied upon arrival at TUSVM Wildlife Clinic. From 1989-1992, 124 loons (60 adults, 28 immature, 27 chicks, 4 embryos, and 5 of unknown age) were examined.

Necropsy, Radiography, Histopathology

Dead or moribund common loons were examined to determine if lead toxicosis, lead tissue levels, and the occurrence of fishing sinker ingestion are significantly correlated to mortality. Each cadaver was weighed and a dorso-ventral radiograph obtained. Necropsies were performed during which a standard set of tissues were taken for histopathology examination. When gross lesions were present, they were processed and examined in addition to the standard set of tissues. Liver tissue was taken and stored at -70º C in chemically clean glass containers (I-Chem Research) and subsequently shipped to Hazleton Laboratories for analysis.

Toxicology

Selected toxicologic examination was performed. Liver, kidney, and small intestine were taken at necropsy and stored in I-Chem jars at -70º C prior to analysis. Chemical analysis of tissue was performed by Hazleton Laboratories, Madison, Wisconsin and quality assurance by the U.S. Fish and Wildlife Service Patuxent Analytical Control Facility. Liver samples were analyzed for a number of metals. Analysis included aluminum, arsenic, barium, beryllium, boron, cadmium, chromium, copper, iron, lead, magnesium, manganese, mercury, molybdenum, nickel, selenium, strontium, vanadium, and zinc. Lead concentrations were determined by graphite furnace atomic absorption. The lower limit for lead concentration in liver samples was 0.5 ppm. After digestion and purification steps, mercury concentrations were determined by atomic absorption spectrophotometry (Hatch and Ott 1968). The lower limit for mercury concentration in liver samples was <0.5 ppm. Selenium concentrations were digested and determined fluorometrically (Watkinson 1966). The lower limit of detection for fluorometric determination of selenium was <0.1 ppm. Trace elements of interest were measured using the inductively coupled plasma quantometer (ICPQ). Lower limits of detection for trace elements were <0.5 ppm. The remainder of metals were analyzed using inductively coupled plasma-atomic emission spectrometry (Dahlquist and Knoll 1978).

RESULTS

In many cases, pathological findings clearly represented the cause of loon death. In other cases, the sum of multiple sublethal clinical findings may have resulted in loon mortality. Major pathological findings included the diagnosis that 30 birds died due to trauma; while 29 birds were found to have parasites; 28 birds, all adults, had ingested metal (27 with fishing sinkers and one with buckshot); 19 birds were diagnosed with aspergillosis; 18 with bone fractures; 10 with ingested shot; 8 with ingested fishing hooks (some with line and sinker attached); 5 with ingested plastic; 5 chicks with omphalitis (an umbilical infection); and 3 with tumors (Figure 1).

A disturbing finding in this study is the high incidence of metal ingestion in adult loons. Metal ingestion was the single most common pathological finding for adult loons in this study (28 of 60, 47%) (Figure 2). Metal ingestion was defined as the presence of a dense metallic object in the bird's proventriculus or gizzard, other than a fish hook, leader, or swivel. All loons with metal ingestion were adults and all but one were from inland freshwater lakes. Of 40 adults found on freshwater lakes, 27 (67.5%) had ingested metal. Of those bird in which sex could be determined, proportionally more males (64%) than females (36%) had ingested sinkers. With the exception of one buckshot, all ingested metal was in the form of fishing sinkers. Seven loons with ingested sinkers also ingested fish hooks.

Sixty adults (29 males, 26 females, and 5 of undeterminable sex) were collected. The average weight of males was 4.1 kg and the average weight of females was 3.0 kg. In our study, the average weight of adults with lead toxicosis was slightly higher than those without (Table 1). This is contrary to Hohman et al. (1990) who reported a 10% body mass reduction in canvasback ducks (*Aythya valisineria*) that had ingested lead shot. Since loons rarely have large amounts of subcutaneous or visceral fat, these parameters are of little use in evaluating body condition. In this study, a combination of pectoral muscle atrophy and body weight was used. In loons, a correlation of beak and tarsus measurements with body weights may be more reliable and uniform indicators of body condition.

Major Pathologic Findings

In birds which had ingested lead, necropsy results were varied with no single finding predominating. In two birds, the proventriculus and thoracic esophagus were distended and impacted with crayfish. While proventricular distention is a common occurrence in waterfowl lead toxicosis (Friend 1987), this clinical sign may also be associated with other diseases such a avian cholera (Wobeser 1981). In the present study, loons with ingested lead rarely exhibited the bile-stained gizzard lining and green colored vent feathers reported in chronic toxicosis in waterfowl (Friend 1987). Absence of these signs may be indicative of a species difference or a difference between acute and chronic disease states (Friend 1987, Humphreys 1991). Most of the loons with lead toxicosis were presented in good body condition, which may imply that the mortality is due to acute exposure.

Although entanglement in monofilament line was responsible for several deaths, ingested monofilament and swivels appear to result in no pathology. Ingested fish hooks were occasionally associated with small granulomas in the proventriculus or gizzard wall, but usually caused little pathology. In three cases, hooks penetrated the gastrointestinal tract and caused abdominal adhesions. In one case, a hook resulted in a fatal peritonitis. The metal

composition of hooks may be a major variable contributing to their persistence and traumatic effect.

Tissue Analyses

Tissues from 38 loons (25 adults, 8 immature, and 5 chicks) were analyzed for metals and trace elements. Lead, mercury, aluminum, selenium, and cadmium were found in elevated concentrations (Table 2).

Lead

Chemical analyses of liver samples was performed to establish 1) background lead concentrations in loons, and 2) lead concentrations in adults that had swallowed metallic objects. In adults, lead concentrations ranged from <0.05 to 22.60 ppm. The average concentration in immatures was <0.50 ppm, and the average concentration in chicks was 0.68 ppm (Table 3).

In most cases, metal ingestion was accompanied by lead toxicosis. Liver lead concentrations of birds known to have ingested metal ranged from <0.50 to 18.00 ppm, with a mean of 10.97 ppm (Table 3). Lead toxicosis was considered to exist when lead liver concentration was 5.00 ppm or above. Adults with clinical signs of lead toxicosis had liver concentrations which ranged from 5.03 to 22.60 ppm. Of these adults, the average male weight was 4.4 kg and the average female weight was 4.0 kg. Adults without clinical indications of lead toxicosis were all below 0.50 ppm. Of these adults, the average male weight was 4.1 kg and the average female weight was 2.5 kg.

One bird that ingested a sinker had a liver lead concentration (<0.50 ppm) well below the presumptive lead toxicosis criterion of 5.0 ppm. Liver lead concentrations of birds that lacked ingested metal ranged from <0.05 to 22.60 ppm ($\bar{x}$=2.75 ppm). We speculate that this was a newly ingested sinker and had not been assimilated, the sinker may not have been made from lead, or a labeling error was made with this sample. Further tests on this sample are pending.

Mercury

Mercury analysis of liver samples from the 38 loons established adult concentrations which ranged from 1.18 to 110.00 ppm ($\bar{x}$=28.72 ppm) (Table 2). Liver concentrations in thirteen adult males ranged from 1.18 to 110.00 ppm ($\bar{x}$=39.09 ppm). The twelve adult females sampled had liver mercury levels from 2.31 to 52.40 ppm ($\bar{x}$=17.07 ppm). Immature loons had mercury liver concentrations from 3.03 to 18.40 ppm ($\bar{x}$=9.62 ppm). Mercury concentrations in loon chicks ranged from 0.35 to 3.45 ppm ($\bar{x}$=1.20 ppm).

Liver mercury levels were characterized as being elevated when they exceeded 20.0 ppm. Nine (69.2%) of the adult males had elevated mercury levels. Eight males with elevated mercury had a mean body weight of 4.14 kg, compared to the adult males with liver mercury levels less than 20 ppm, who had a mean weight of 4.44 kg. Three (25.0%) adult females had elevated liver mercury levels; 21.30, 37.50, and 52.40 ppm. Their mean body weight

was 2.73 kg, compared to the adult females without elevated mercury levels which had a mean weight of 3.14 kg.

Aluminum

Liver aluminum concentration was at or below the detection limit in all adults except one, which had a liver level of 8.02 ppm. While the detection limit varied for immatures from 0.98 to 5.0 ppm, one immature loon was found to be above it's detection limit at 2.2 ppm. However, of the five chicks analyzed, three were found to have whole-body aluminum levels of 1.46, 17.2, and 15.6 ppm.

Cadmium

The liver cadmium level in adults ranged from 0.82 to 4.66 ($\bar{x}$=1.80 ppm). Concentrations in immatures ranged from 0.06 to 1.86 ($\bar{x}$=0.68 ppm). Cadmium was not detected in any of the chicks.

Selenium

Liver selenium levels in adults extended from 1.67 to 29.30 ppm ($\bar{x}$=10.21 ppm). Immature loon liver levels ranged from 0.82 to 8.20 ($\bar{x}$=4.36 ppm). The concentration of selenium in chicks ranged from 0.43 to 1.41 ($\bar{x}$=0.85 ppm).

DISCUSSION

Lead

Lead toxicosis may have a significant affect on loon populations in New England because it affects those birds of breeding age on their breeding grounds. Locke et al. (1981) reported on three common loons from Maine, New Hampshire, and Wisconsin that died from ingestion of lead sinkers. Lead ingestion has been reported to be a problem in other avian species as well. A recent study of mute swans (*Cygnus olor*) in England (Sears et al. 1989) reported fifty-five percent of swans found moribund or debilitated had ingested lead sinkers. This was the single greatest cause of illness observed in swans during a four year period.

In healthy waterfowl Clemens et al. (1975) has reported lead levels of 2.0 ppm and 5.0 ppm in liver and kidney, respectively. Lead liver levels of >6.0 ppm (Friend 1987, Longcore et al. 1974) are thought to be toxic in waterfowl. Liver lead concentrations in the lead-poisoned loons reported by Locke et al. (1981) were 20.6, 46.1, and 38.5 ppm (wet weight) as compared to liver lead concentrations of loons that died from other causes (0.05-0.5 ppm). These concentrations are slightly higher than those found in loons in our study (<0.50-18.0 ppm in birds with ingested metal) (Table 3).

Two loons in which no ingested metal was found had elevated liver lead levels (0.41 and 22.6 ppm). Studies in Anserformes have demonstrated that blood lead values are a more sensitive indicator of lead poisoning than the presence of ingested pellets in the gizzard (Anderson and Havera 1986). It is speculated that this is because very small lead objects may be completely digested or excreted before the bird dies. The same circumstances may explain the elevated lead levels in these two loons.

Once in the gizzard, the sinkers are gradually eroded. Lead compounds are then available for absorption from the digestive tract into the blood and on to other organs (Humphreys 1991). Short term or acute lead poisoning is often detected in the blood. Long term or chronic lead poisoning is often observed from high levels in organs such as the liver and kidney where lead can be stored for long periods of time. Despite medically sophisticated efforts, most live loons that are found with ingested lead die (Pokras, pers. comm.).

It is difficult to determine why adult birds are ingesting lead sinkers. The lead sinkers are sometimes ingested along with fish hook, swivel, and monofilament line (4/28 loons with ingested sinkers). The sinkers are similar in size to the pebbles found in the gizzards of these birds. It is not known if the birds are mistakenly ingesting the sinkers along with the pebbles normally found in their gizzards, if they are selecting and ingesting the sinkers, or if they are eating live baitfish with hooks and sinkers attached to them. The buckshot found in the gizzard of one loon may suggest that the metal was ingested independently.

Mercury

Mercury was found to be the most frequently elevated contaminant in liver tissue. The minimum liver level in raptors suffering acute mercury toxicity has been reported to be between 20 and 45 ppm (Scheuhammer 1987, Noble and Elliott 1990). Wobeser (1981) reported that mercury levels >10.0 ppm in the liver may be high enough to cause clinical signs or even reproductive impairment in waterfowl. Frank (1983) reported liver mercury levels in healthy loons ranged from 1.92 to 6.35 ppm versus emaciated loons with mercury levels of 16.0 to 26.4 ppm. Barr (1986) found that loons with mercury liver levels around 40 ppm fledged fewer young per territorial pair and were significantly lighter in weight than loons with lower mercury levels. These levels associated with impairment are similar to elevated mercury levels reported in the study. In this study both males and females with elevated mercury levels had a lower mean body weight as well.

Aluminum

An elevated liver aluminum level was detected in one adult, however it was too autolyzed to detect any of the pathologic signs associated with aluminum toxicity. One immature loon with an aluminum level of 2.2 ppm also had a luxated cervical vertebra. Sparling (1991) demonstrated that ducks fed diets
high in aluminum often show clinical signs of lameness, decreased bone elasticity, bone fractures, and death. Aluminum levels in chicks were significantly higher than those found in adults and immatures. This may have been due to analyzing whole chicks instead of portions of the liver.

Cadmium

Cadmium levels in the liver were higher for the adults, which appears to imply that cadmium bioaccumulates in loons. Mean cadmium levels recorded in adults was 1.80 ppm, 0.68 ppm for immature loons, and 0.06 ppm in loon chicks. These were higher than values found in Louisiana herons (*Hydranassa tricolor*) (Cheney et al. 1981). Cheney reported mean cadmium levels of 0.078 ppm in adults and 0.024 ppm in chicks.

Selenium

Selenium levels in loon livers were higher for the adults, which may imply that selenium bioaccumulates in loons. In waterfowl exhibiting toxic effects, Ohlendorf et al. (1988) reported a mean liver selenium concentration of 94.4 ppm dry weight (approximately 24 ppm wet weight). Control birds were reported to have values nearly an order of magnitude less, with a range of 8.3 to 12.2 ppm dry weight. Our study included three adults (all male) with selenium levels of 20.4, 21.1, and 29.3 ppm (wet weight). In Ohlendorf's study adult birds with elevated selenium concentrations were emaciated and had extensive hepatic lesions and fluid and fibrin in the peritoneal cavity. All three birds in the present study were in good flesh and none suffered the lesions described by Ohlendorf. From the present data it is difficult to discern the role selenium played in the death of these birds. Embryonic mortality and congenital malformations (i.e. microphthalmia, amelia, and abnormal beaks) have been associated with increased levels of selenium (Hoffman and Heinz 1988, Ohlendorf et al. 1988, Heinz et al. 1989).

CONCLUSIONS

This preliminary study provides an overview of environmental factors affecting the common loon in the Northeast United States. While this survey may not give a complete representation of regional loon populations in the Northeastern States, we feel it raises important issues and questions. Adult loons are being adversely effected by environmental contaminants, most notably lead. For a species susceptible to human disturbance (e.g. boating, recreational activities, and shoreline development) the incidence of lead ingestion may have serious consequences for breeding loons.

This study also shows that several metals should be considered as threats to breeding populations of loons and other piscivorous species. In the future we hope to expand the range of our study to include other avian piscivores and to further quantify environmental contaminants.

Figure 1. Major pathological findings in common loons (*Gavia immer*) from the Northeast United States (144 individuals).

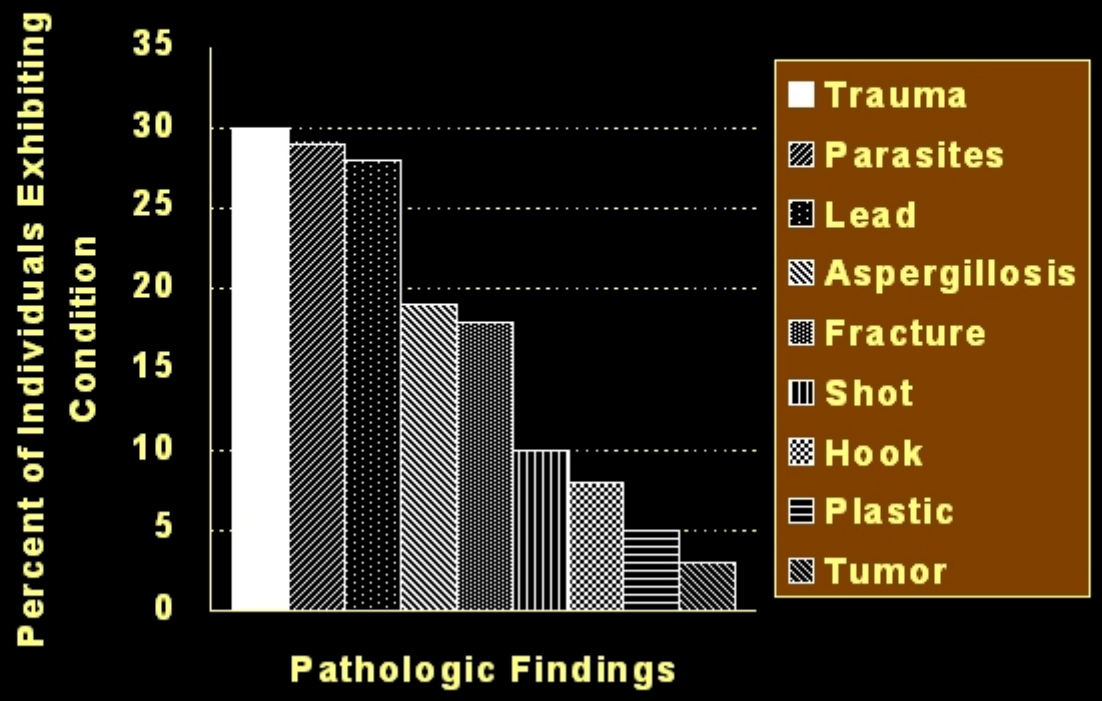

Figure 2. Major pathological findings in adult common loons (*Gavia immer*) from the Northeast United States (60 individuals).

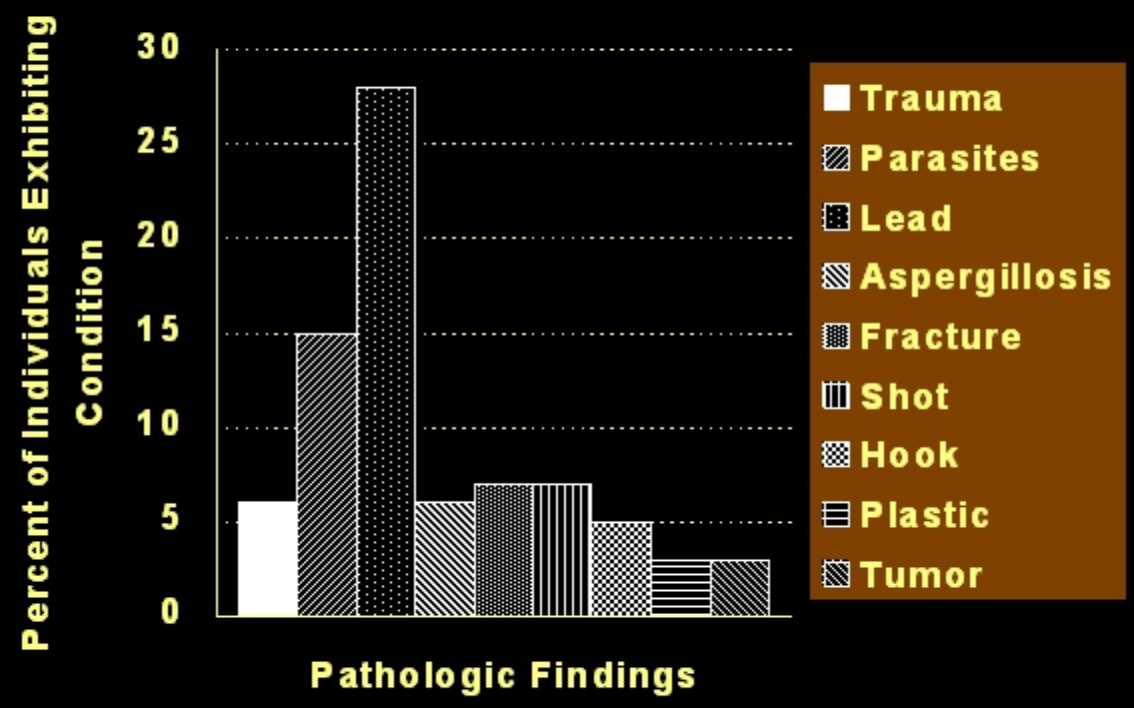

Table 1. Weight of common loons (*Gavia immer*) with liver lead concentrations above and below 5 ppm.

	Weight (kg) of loons w/ liver Pb < 5 ppm	Weight (kg) of loons w/ liver Pb > 5 ppm
No. of Birds	11	12
Range	1.7-5.2	2.8-5.4
Mean	3.091	4.217
Std. Dev.	1.055	0.746
Std. Error	0.318	0.215
Variance	1.113	0.556

Table 2. Metal residues (ppm wet weight) in the livers of common loons (*Gavia immer*) from the Northeast United States 1989-1992.

Contaminant and Age	n	$\overline{x}$	(SD)	Range	Variance
Lead					
Adults	25	6.73	7.02	<0.05-22.6	49.21
Immatures	8	All<0.05			
Chicks	5	0.67	0.48	<0.05-1.24	0.23
Mercury					
Females	12	17.07	14.64	2.31-52.40	214.40
Males	13	39.09	31.52	1.18-110.0	993.24
Immatures	8	9.616	5.98	3.03-18.40	35.74
Chicks	5	1.199	1.29	0.346-3.45	1.65
Cadmium					
Adults	25	1.80	1.05	0.82-4.66	1.11
Immatures	8	0.68	0.65	0.06-1.86	
Chicks	5	All<0.06			
Aluminum					
Adults	25	2.03	1.93	0.98-8.02	3.73
Immatures	9	2.35	1.58	0.98-5.00	2.50
Chicks	5	8.05	7.79	0.98-17.20	60.83
Selenium					
Adults	23	10.21	7.14	1.67-29.30	50.97
Immatures	5	4.36	3.05	0.82-8.20	9.30
Chicks	4	0.85	0.49	0.43-1.41	0.24

Table 3. Liver lead levels (ppm wet weight) of common loons (*Gavia immer*) with and without ingested lead sinkers.

	Loons with no lead in gizzard	Loons with lead in gizzard
No. of Birds	13	12
Range	<0.05-22.6[a]	5.03-18.00
Mean	2.752	10.973
Std. Dev.	6.472	4.938
Std. Error	1.795	1.425
Variance	41.888	24.381

[a]Includes one sample with 9 ppm and one sample with 22.6 ppm

REFERENCES

Anderson, W. L. and S.P. Havera. 1986. Blood lead, protopotphyrin, and ingested shot for detecting lead poisoning in waterfowl. Proceed. of symposium held March 1984 on lead poisoning in wild waterfowl: 10. Edited by J.S. Feierabend and A.B. Russell. Int. Assoc. of Fish and Wildlife Agencies. Washington, D.C.

Barr, J.F. 1986. Population dynamics of the common loon (Gavia immer associated with mercury-contaminated waters in northwestern Ontario. Canadian Wildlife Service. Occasional Paper 56.

Belant, J.L. and R.K. Anderson. 1990. Environmental Contaminants in Common Loons from Northern Wisconsin. The Passenger Pigeon. 52(4).

Birkhead, M. 1982. Causes of mortality in the mute swan (*Cygnus olor*) on the River Thames. J. Zool. London. 198:15-25.

Birkhead, M. 1983. Factors affecting the breeding success of the mute swan (*Cygnus olor*). J. Animal Ecol. 52:727-741.

Blus, L.J., R.K. Stroud, B. Reiswig, and T. McEneaney. 1989. Lead poisoning and other mortality factors in trumpeter swans. Environ. Toxicol. and Chem. 5:263-271.

Borkenhagen, P. 1979. Lead poisoning of waterfowl. Z. Jagdwiss. 25:178-179.

Cheney, M.A., C.S. Hacker, and G.D. Schroder. 1981. Bioaccumulation of lead and cadmium in the Louisiana heron (*Hydranassa tricolor*) and the cattle egret (*Bubulcus ibis*). Ecotox. and Environ. Safety. 5:211-224.

Clemens, E.T., L.Krook, A.L. Aronson, and C.E. Stevens. 1975. Pathogenesis of lead shot poisoning in mallard duck. Cornell Vet. 65: 248.

Dahlquist, R. L., and J.W. Knoll. 1978. Inductively coupled plasma-atomic emission spectrometry: analysis of biological materials and soils for major, trace, and ultra trace elements. Appl. Spectro. 32:1-29.

Erne, K. and K. Borg. 1969. Lead poisoning in Swedish wildlife. In: Metals and Ecology: A Symposium. Natl. Vet. Inst. Stockholm, Sweden. pp 31-33.

Frank, R. 1983. Residues of organochlorine insecticides, industrial chemicals, and mercury in eggs and in tissue taken from healthy and emaciated common loons, Ontario, Canada, 1968-1980. Arch. Environ. Contam. Toxicol. 12:641-654.

Friend, M. 1987. Lead poisoning. In: Friend, M. Field Guide to Wildlife Diseases. U.S. Fish and Wildlife Service Resource Publication. 167: 175-189.

Goode, D.A. 1981. Lead Poisoning in Swans. Report of the Nature Conservancy Council's Working Group. Huntingdon, England.

Haseltine, S.D., J.S. Fair, S.A. Sutcliffe, and D.M. Swineford. 1983. Trends in organochlorine and mercury in eggs and tissue of healthy and emaciated common loon

(*Gavia immer*) eggs from New Hampshire. Trans. of the Northeast Sect., The Wildl. Soc. 40:131-141.

Hatch, W.R. and W.L. Ott. 1968. Determination of sub-microgram quantities of mercury by atomic absorption spectrophotometry. Anal. Chem. 40:2085-2087.

Heinz, G.H., D.J. Hoffman, and L.G. Gold. 1989. Impaired reproduction of mallards fed an organic form of selenium. J Wildl. Manage. 53:418-428.

Hoffman, D.J. and G.H. Heinz. 1988. Embryonic and teratogenic effects of selenium in the diet of mallards. J. Toxicol. Environ. Health. 24:477-490.

Hohman, W.L., R.D. Pritchert, R.M. Pace III, D.W. Woolington, and R. Helm. 1990. Influence of ingested lead on body mass of wintering canvasbacks. J. Wildl. Man. 54(2): 211-215.

Humphreys, D.J. 1991. Effects of exposure to excessive quantities of lead on animals. Br. Vet. J. 147: 18-30.

Kraft, M. 1984. Lead Poisoning. Are we wasting our waterfowl? Kansas Wildlife. 41:13-20.

Locke, L.S., S.M. Kerr, and D. Zoromski. 1981. Lead poisoning in common loons (*Gavia immer*). Av. Dis. 26: 392-396.

Longcore. J.R., L.N. Locke, G.E. Bagley, and R.Andrews. 1974. Significance of lead residues in mallard tissues. Special Science Report Wildlife. U.S. Fish and Wildlife Service Publication 182. Washington, D.C.

McIntyre, J.M.W. 1988. The common loon: spirit of the northern lakes. U. Minnesota Press.

Noble, D.J. and J.E. Elliott. 1990. Levels of contaminants in Canadian raptors, 1966 to 1988; effects and temporal trends. Canadian Field-Naturalist. 104:222-243.

Ohlendorf, H.M., A.W. Kilness, J.L. Simmins, R.K. Stroud, D.J. Hoffman, and J.F. Moore. 1988. Selenium toxicosis in wild aquatic birds. J. Toxicol. Environ. Health. 24:67-92.

Pokras, M.A. and R.Chafel. 1992. Lead toxicosis from ingested fishing sinkers in adult common loons (*Gavia immer*) in New England. J. Zoo and Wild. Med. 23:92-97.

Poppenga, R.H. 1992. Liver and kidney metal concentrations from a series of common loons determined by inductively coupled argon plasma emission spectroscopy. In: Symposium on the Loon and its Ecosystem: Status, Management, and Environmental Concerns. College of the Atlantic, Bar Harbor, Maine.

Ream, C.H. 1976. Loon productivity, human disturbance, and pesticide residues in northern Minnesota. Wilson Bulletin. 90:637-640.

Sanderson, G.C. and F.C. Bellrose. 1986. A review of the problem of lead poisoning in waterfowl. Illinois Nat. Hist. Surv. Special Publication 4:1-34.

Scheuhammer, A.M. 1987. The chronic toxicity of aluminum, cadmium, mercury, and lead in birds: a review. Environmental Pollution. 71:329-375.

Sears, J.S., W. Cooke, Z.R. Cooke, and T.J. Heron. 1989. A method for the treatment of lead poisoning in the mute swan (*Cygnus olor*) and its long-term success. Br. Vet. J. 145: 586-595.

Sparling, D.W. 1991. Acid precipitation and food quality: Effects of dietary aluminum, calcium, and phosphorous on bone and liver characteristics in American black ducks and mallards. Arch. Environ. Contamin. Toxicol. 21:281-288.

Watkinson, J.H. 1966. Flourometric determination of selenium in biological material with 2,3 diaminonaphthalene. Anal. Chem. 38:92-96.

Wobeser, G.A. 1981. Diseases of waterfowl. Plenum Publishing, New York, NY.