

DISTINGUISHING REAL VS FAKE TIGER PENISES

Identification Guides for Wildlife Law Enforcement No. 6

Bonnie C. Yates
National Fish and Wildlife Forensics Laboratory
1490 East Main Street
Ashland, OR 97520

Email: bonnie_yates@fws.gov

March 2005

Introduction

Dried genitalia are an important element of traditional medicine in many cultures around the world. Because genitalia are usually prescribed dried and whole, they are generally recognizable. Preparation for sale of the genitals consists of removal of hair and all or most of the skin. In some cases, the *glans penis* is altered to attempt replication of the sex organs of iconographically important species such as deer, seal, or tiger. Organs that are purportedly from these species can be sold at inflated prices. As certain species become more rare or receive greater protection, the cultures that hold them in high esteem devise substitutes for use in adornment, rituals, and medicinals. Wildlife law enforcement officers can learn to differentiate the various species sources of these products and detect genuine tiger penises from the abundant fakes currently being sold to unsuspecting tourists and consumers.

In animal markets, some parts and products are not what they are labeled. One of the most difficult products to identify has been genuine dried tiger penises. The reason for this is the rarity of the real thing and a long tradition of the production of "lesser tiger" or tiger substitute, that is, any other large mammal that can be promoted as a replacement for tiger. When rehydrated and consumed in a soup or tea, this product is believed to serve as an aphrodisiac or restorative tisane. To date, no dried penis from an actual tiger has been seen in the Lab as evidence in a wildlife case.

Penises

Genuine tiger genitalia are unlikely to be found for sale in a public shop or market. What is sold as tiger usually comes from cattle — after undergoing some modification. The accurate identification of genitalia from tiger (*Panthera tigris*) can be achieved only by knowledge of what a genuine tiger penis looks like and by comparison with modified and unmodified penises of other species.

Penises of cats are known to have barbs on the tips (Figs. 1 and 2). This is thought to be a mechanical means of inducing ovulation. The morphological reality is that both the

penis tip (~ 2 cm), and these barbs or spicules are very small (< 0.7 mm) in even the largest cats and are barely noticeable when the penis is dried.

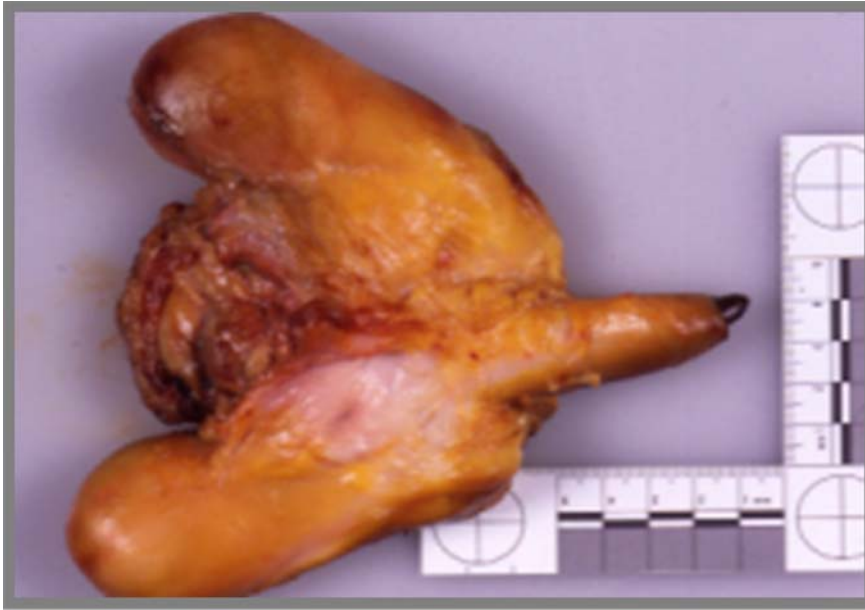

Fig. 1. Genuine tiger penis, raw state. Underneath the foreskin of a real tiger's penis is the *glans*, which is studded with small spicules called barbs (See close-up in Fig. 2).

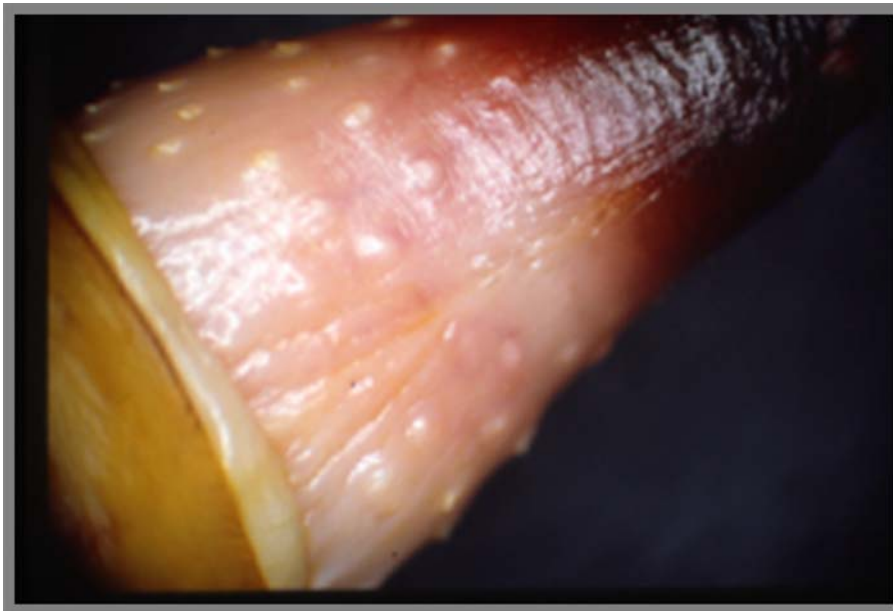


Fig. 2. Close-up of tip of tiger penis shown in Fig. 1.

Because genuine tiger penises are so rare, the buying public apparently no longer knows what a real tiger penis looks like. Artisans, therefore, must fabricate barbed penises out

of cattle and deer genitals to replicate an appearance based on myth and public demand. Figure 3 shows a genuine tiger penis that has been dried. Figure 3 includes a photograph showing the shape and position of the *os penis* or baculum of a tiger that is found inside the penis tip. Notice in the close-up (Fig. 3) that the *glans penis* (tip) is less than 2 inches (~ 5 cm) and that the barbs are imperceptible in the close-up view (lower right).

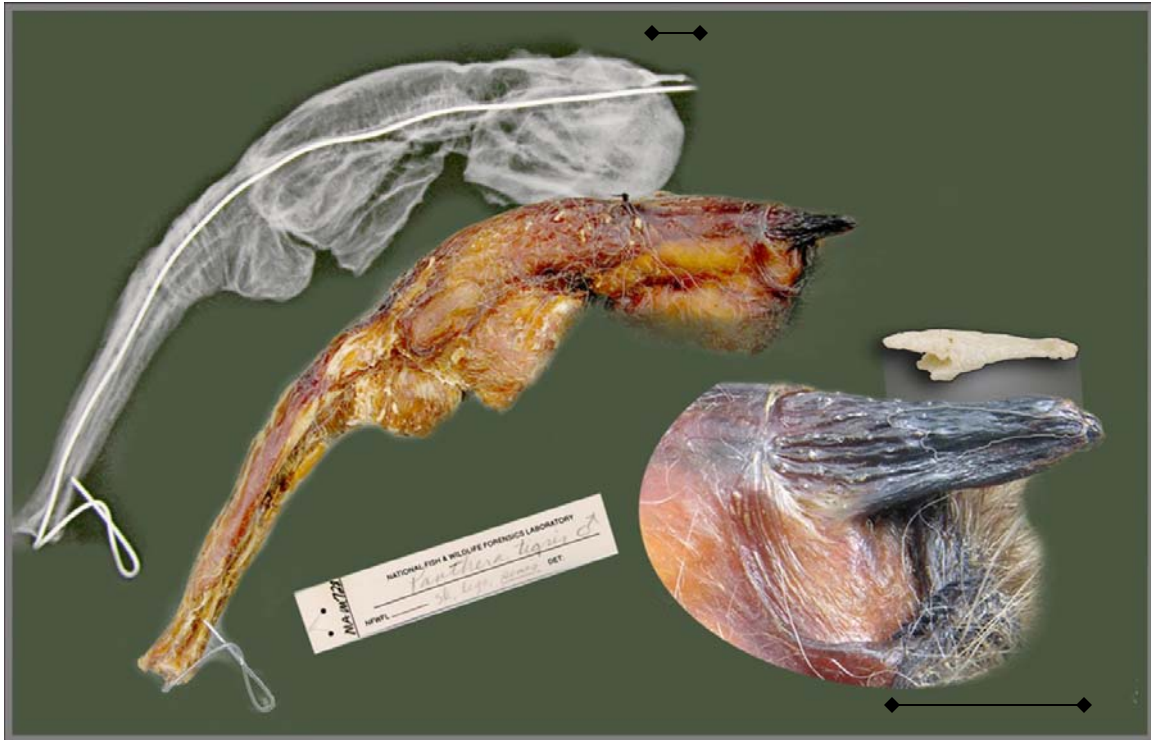


Fig. 3. Dried tiger penis, whole (upper as x-rayed and middle as photographed), and close-up of tip (lower right), showing the approximate position of the internal penis bone, also known as a baculum. Both scale lines represent approximately 2 cm.

In order to replicate these barbs, skilled craftsmen take the organs of slaughtered cattle and fabricate barbs by making tiny V-shaped cuts (Fig. 4) over the surface of the glans penis. Then by hanging the modified penis upside down, the edges of these little cuts curl under during drying and form a barb-like projection. The glans may be densely covered in very small barbs or sparsely covered by large (up to 1 cm) projections, depending on skill and desired appearance. Some of these bovine organs are tipped with three curled appendages, or the tips may be pierced with a hole for suspension (Fig. 5).

Large dried genitalia with barbed tips are frequently interdicted for a variety of reasons: (a) they are found with price tags exceeding \$200; (b) they are unusual in appearance; or (c) they are advertised as penises from tigers (*Panthera tigris*), a species listed in the U.S. Endangered Species Act and on CITES Appendix I.

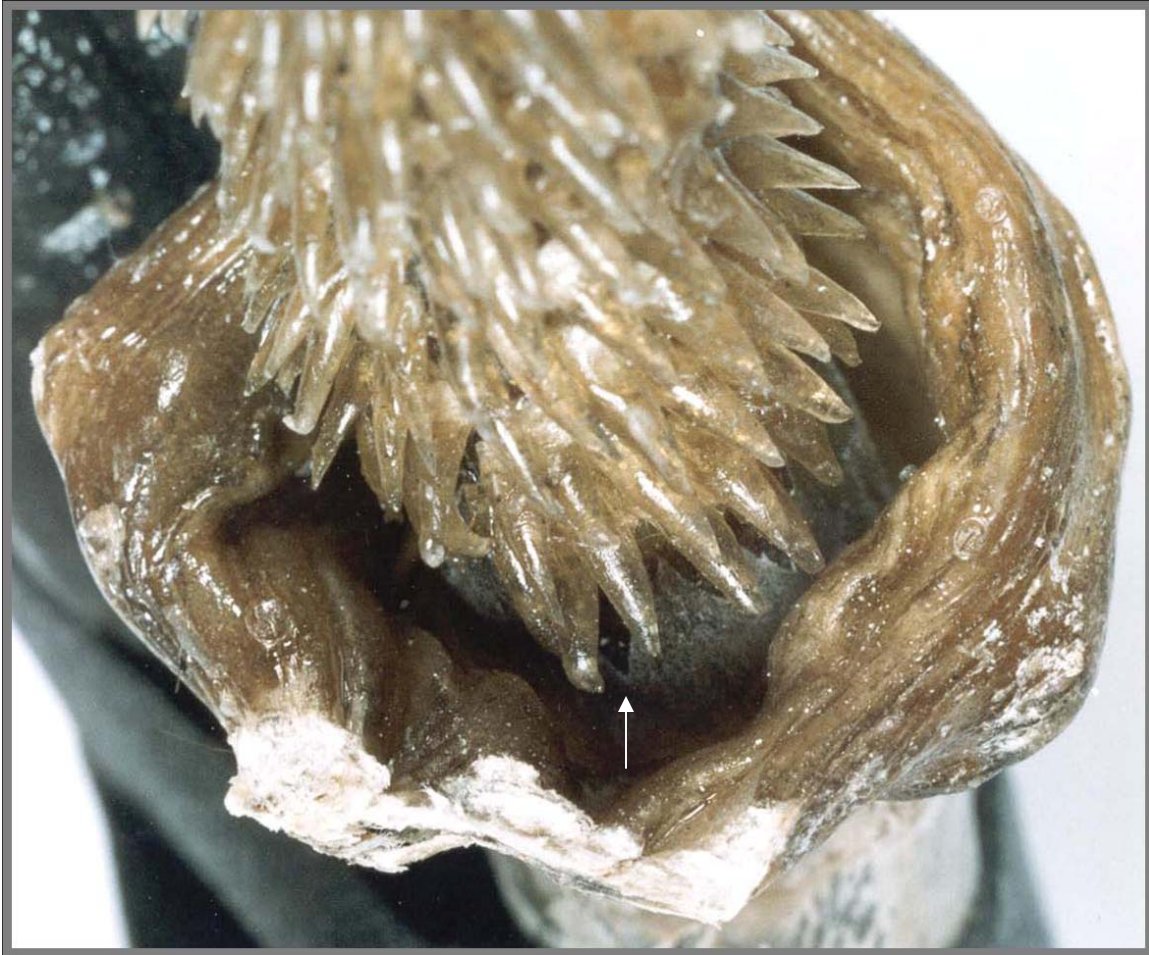

Fig. 4. Looking at the base of a bull's penis carved to simulate a tiger's penis. This is how cattle genitals are made to be used as replacements for genuine tiger parts. Notice the V-shaped cuts in the tissue underneath the lowest barbs (arrow).

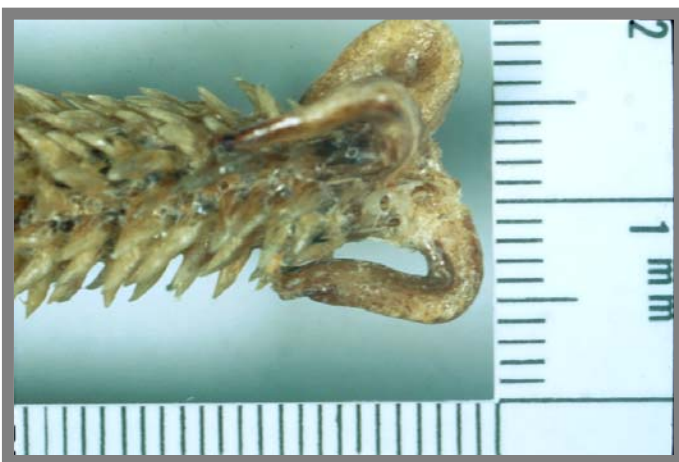

Fig. 5. Extravagantly carved tip of a bull's penis.

Genitals of other domestic mammals have been dried and sold as tiger penises. For example, horses and dogs have been used as substitutes. They are sliced and consumed as tea or soup as traditional medicine for strength and virility. Unlike tiger penises, however, deer, horse, and cattle penises lack a baculum. Figures 6 and 7 show specimens of cattle and horse.

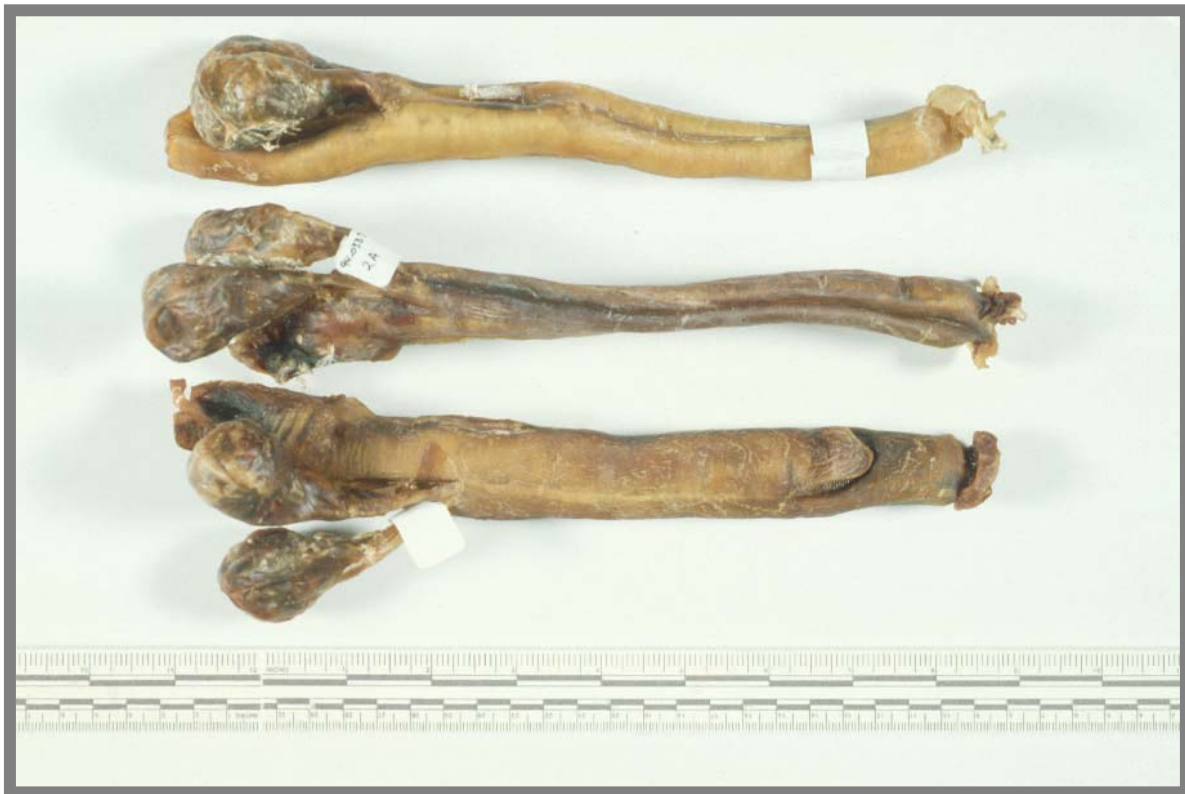

Fig.6. Examples of cattle (upper and middle) and horse (lower) genitalia.

Not all dried penises are sold as tiger; attributes of many other animals are considered desirable in traditional medicines. Another example of fraud and fakery came in the red leatherette case shown in Figure 7. The lid of the box is adorned with a depiction of male and female deer and lettering that suggests that the contents have a homeopathic effect of either a rejuvenative or aphrodisiacal nature. Alert to the frequent trafficking of genitalia of endangered species, Wildlife Inspectors confiscated the item and sent it to the National Fish and Wildlife Forensics Laboratory for identification of the taxon of origin.

Morphological examination of the contents indicated an elongated dried penis with a thin piece of hairy skin located below the glans. The hairs exhibited the microscopic signature of the deer family, Cervidae. Because this haired patch of dried skin appeared to have free margins around both edges, there was suspicion that the deer skin had been applied to the penis, suggesting that further tests were required to identify the genitals.

Serological analysis using immunodiffusion determined that dried tissue from the *corpus cavernosum* (shaft) of the penis was consistent with bovine tissue. The tests were non-reactive to cervine antisera, indicating that the penis was not tissue from a member of the deer family, but was from a bull and, therefore, from the bovine family.



Fig. 7. A putative deer penis in a decorative box. Serological assay determined the tissues to be bovine.

Domestic dog penises are frequently used as replacements for deer, bear, or seal and may be detected via radiographs (x-rays) (Fig. 8) by the distinctive groove visible on the dorsal surface of internal baculum bone (*os penis*) of the dog. Feral dogs or ranched foxes would be likely canid sources for dried seal penises in the trade. Bear penises may be sold in conjunction with bear gall bladders. They lack the groove shown in examples of canid bacula (Figs. 8 and 9).

Seal bacula may be distinguished by features common to each of the two seal families (Fig 9). The baculum of a young fur seal (*Callorhinus ursinus*) is tapered. Like the fur seal, the bacula of sea lions (*Zalophus californianus* and *Eumetopias jubatus*) are bulbous at the base and flare at the tip (in adults). True seals like the harbor seal (*Phoca vitulina*) and elephant seal (*Mirounga* sp.) do not have the flared tip. Like tiger, seal penises have a strong tradition in Asia not only as medicine, but also in cultural exchange (Walker 1998).

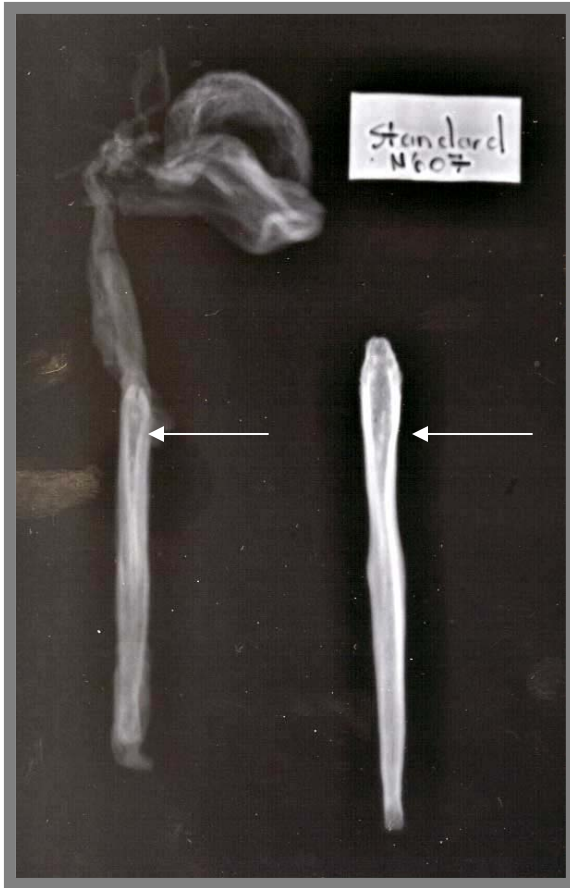

Fig. 8. Radiograph (x-ray) of dried dog genitals on left, showing the presence of the distinctive groove (arrow) in the baculum or *os penis*. At right is an *os penis* bone of a slightly larger dog x-rayed at the same time.

Summary

The penis from a real tiger has a small triangular baculum (Fig. 9), but it is seldom visible even in an x-ray, being obscured by folds in dense, dried tissues (See Fig. 3). The genitalia of other mammals are used in the wildlife trade, and can usually be identified by the size and shape of the internal penis bone or baculum. Sometimes the dried genitals must be macerated or cleaned by dermestid beetles to extract the baculum. X-rays are the best screening tool for initial examination of the dried penis. An expert should be consulted to interpret the radiographs. However, there are some guidelines that can be used to eliminate tiger as a suspected species source when examining dried genitalia. Table 1 summarizes these points.

Table 1

To eliminate tiger, consider the following characteristics:

A dried penis CANNOT be from tiger if

- very obvious barbs or spines cover the tip as in Figs. 4 and 5
(It is probably from a large ungulate. Fig. 6)
- it has a large baculum visible on x-ray; compare to Fig. 3
(It is probably from a carnivore. Fig. 9)
- it is long (>8 inches) from tip to scrotum
(It is probably deer, cattle, or horse. Fig. 6)



Fig. 9. These carnivore bacula might be seen in x-rays of dried genitalia sold for traditional medicines. From top are cleaned penis bones of tiger, true seal (juvenile), fur seal (juvenile), sea lion, brown bear, wolf, and dog. (Scale line is approx. 2 cm long.)

References

Walker, B. (1998). Medical Exchange in Contested Lands: Pharmaceutical Products as Cultural Capital. Paper presented at the Annual Meeting of the Assn for Asian Studies, March 26-29, Washington, DC.

Yates, B.C. (2000). Recognition of tiger parts in trade. In *Far from a Cure: The tiger trade revisited*, edited by K. Nowell, pp. 90-96. TRAFFIC International.

Yates, B.C., P.A. Dratch, and E. Cooper (1995). Manipulated genitalia: Evidence of fraud in the wildlife medicinal trade. Poster presented at The Wildlife Society Annual Conference, Portland, Oregon.