This article was downloaded by: [US Fish & Wildlife Service]
On: 29 December 2011, At: 05:37
Publisher: Taylor & Francis
Informa Ltd Registered in England and Wales Registered Number: 1072954 Registered office: Mortimer House, 37-41 Mortimer Street, London W1T 3JH, UK




North American Journal of Aquaculture
Publication details, including instructions for authors and subscription information:
http://www.tandfonline.com/loi/unaj20

# Safety of Aquaflor-Medicated Feed to Sunshine Bass

David L. Straus [a], James D. Bowker [b], Molly P. Bowman [b], Dan Carty [b], Andrew J. Mitchell [a] & Bradley D. Farmer [a]

[a] U.S. Department of Agriculture, Agricultural Research Service, Harry K. Dupree-Stuttgart National Aquaculture Research Center, Post Office Box 1050, Stuttgart, Arkansas, 72160, USA

[b] U.S. Fish and Wildlife Service, Aquatic Animal Drug Approval Partnership Program, 4050 Bridger Canyon Road, Bozeman, Montana, 59715, USA

Available online: 28 Dec 2011

To cite this article: David L. Straus, James D. Bowker, Molly P. Bowman, Dan Carty, Andrew J. Mitchell & Bradley D. Farmer (2012): Safety of Aquaflor-Medicated Feed to Sunshine Bass, North American Journal of Aquaculture, 74:1, 1-7

To link to this article: http://dx.doi.org/10.1080/15222055.2011.630262

PLEASE SCROLL DOWN FOR ARTICLE

Full terms and conditions of use: http://www.tandfonline.com/page/terms-and-conditions

This article may be used for research, teaching, and private study purposes. Any substantial or systematic reproduction, redistribution, reselling, loan, sub-licensing, systematic supply, or distribution in any form to anyone is expressly forbidden.

The publisher does not give any warranty express or implied or make any representation that the contents will be complete or accurate or up to date. The accuracy of any instructions, formulae, and drug doses should be independently verified with primary sources. The publisher shall not be liable for any loss, actions, claims, proceedings, demand, or costs or damages whatsoever or howsoever caused arising directly or indirectly in connection with or arising out of the use of this material.

*North American Journal of Aquaculture* 74:1–7, 2012
American Fisheries Society 2012
ISSN: 1522-2055 print / 1548-8454 online
DOI: 10.1080/15222055.2011.630262

ARTICLE

# Safety of Aquaflor-Medicated Feed to Sunshine Bass

**David L. Straus***
*U.S. Department of Agriculture, Agricultural Research Service,*
*Harry K. Dupree–Stuttgart National Aquaculture Research Center, Post Office Box 1050, Stuttgart,*
*Arkansas 72160, USA*

**James D. Bowker, Molly P. Bowman, and Dan Carty**
*U.S. Fish and Wildlife Service, Aquatic Animal Drug Approval Partnership Program,*
*4050 Bridger Canyon Road, Bozeman, Montana 59715, USA*

**Andrew J. Mitchell and Bradley D. Farmer**
*U.S. Department of Agriculture, Agricultural Research Service,*
*Harry K. Dupree–Stuttgart National Aquaculture Research Center, Post Office Box 1050, Stuttgart,*
*Arkansas 72160, USA*

Downloaded by [US Fish & Wildlife Service] at 05:37 29 December 2011

***Abstract***

**Aquaflor (florfenicol, 50% type A medicated article) is a relatively new antibiotic used in U.S. aquaculture and has been widely accepted as a safe and effective therapeutant. Some peer-reviewed studies have suggested that 15 mg florfenicol (FFC)·kg$^{-1}$ body weight (BW)·d$^{-1}$ for 10 d controls mortality to a greater extent than 10 mg FFC·kg$^{-1}$ BW·d$^{-1}$ for 10 d. This study evaluated the safety of Aquaflor to sunshine bass (female white bass *Morone chrysops* × male striped bass *M. saxatilis*) when administered in feed at 15 (1× the maximum proposed therapeutic dose), 45 (3×), and 75 (5×) mg FFC·kg$^{-1}$ BW·d$^{-1}$ for 20 d (2× the currently approved 10-d treatment duration). The medicated feed was top-coated with Aquaflor and fed at 2% BW·d$^{-1}$ divided equally between the morning and afternoon feedings. Juvenile sunshine bass (13.6 ± 1.6 g [mean ± SD]) were stocked into 100-L flow-through tanks at 20 fish per tank. Diets were randomly assigned to three replicate tanks per treatment; fish in three additional nonstudy tanks were fed control diets and weighed weekly to calculate proper feeding quantities. Throughout the trial, water quality was maintained within ranges suitable for sunshine bass culture, fish behavior appeared normal, and all feed was readily and rapidly consumed. There were no mortalities and fish health evaluations revealed no chronic toxicity patterns. None of the histopathologies distinctive to the use of Aquaflor were observed. In conclusion, there is an adequate margin of safety associated with administering Aquaflor-medicated feed to fingerling sunshine bass at the proposed therapeutic treatment regimen of 15 mg FFC·kg$^{-1}$ BW·d$^{-1}$ for 10 d.**

Bacterial diseases can cause significant losses of fishes reared in captivity (Clarke and Scott 1989; Frerichs and Roberts 1989; Bjorndal 1990); therefore, the judicious use of antimicrobial therapy can play an important role in aquaculture (Klontz 1987; Alderman 1988). Florfenicol ([R-(R*, S*)]-2, 2-dichloro-N-[1-(fluoromethyl)-2-hydroxy-2-[4-(methylsulfonyl) phenyl] ethyl-acetamide) is a potent, broad-spectrum, antibacterial agent with bacteriostatic and bacteriocidal properties against a variety of Gram-positive and Gram-negative bacteria (Horsberg et al. 1996). Florfenicol (FFC) is effective against furunculosis in Atlantic salmon *Salmo salar* (Nordmo et al. 1994; Samuelsen et al. 1998), pseudotuberculosis in yellowtail (buri) *Seriola quinqueradiata* (Yasunaga and Yasumoto 1988), and *Edwardsiella tarda* infections in Japanese eel *Anguilla japonica* (Fukui et al. 1987). Because of its effectiveness and minimal risk to human health when used in food-producing animals, FFC has become

*Corresponding author: dave.straus@ars.usda.gov
Received September 30, 2010; accepted April 8, 2011

Downloaded by [US Fish & Wildlife Service] at 05:37 29 December 2011

an important veterinary therapeutic drug when administered in feed (T. E. Powers, K. J. Varma, and J. D. Powers, abstract presented at the 4th Congress of the European Associations of Veterinary Pharmacology and Toxicology, 1988).

Florfenicol appears to exhibit a reasonable margin of safety to target animals when exposure exceeds recommended dosage rates and treatment periods. Gaikowski et al. (2003) showed that FFC caused no mortalities, differences in growth, or differences in clinical observations in channel catfish *Ictalurus punctatus* fed for 20 d at doses up to 34.9 mg FFC·kg$^{-1}$ body weight (BW)·d$^{-1}$. Similar results were observed in rainbow trout *Oncorhynchus mykiss* fed a nominal dose of 50 mg FFC·kg$^{-1}$ BW·d$^{-1}$ for 20 d (R. G. Endris, Intervet/Schering-Plough Animal Health, personal communication).

Aquaflor is an aquaculture feed premix containing 50% FFC and is approved in more than 20 countries for controlling bacterial diseases in cultured fishes. The U.S. Food and Drug Administration (FDA) Center for Veterinary Medicine (CVM) has approved Aquaflor for use in feed at 10 mg FFC·kg$^{-1}$ BW·d$^{-1}$ for 10 d to control mortality in (1) catfish due to enteric septicemia associated with *E. ictaluri*, (2) freshwater-reared salmonids due to coldwater disease associated with *Flavobacterium psychrophilum*, and (3) freshwater-reared salmonids due to furunculosis associated with *Aeromonas salmonicida*. Aquaflor-CA1 has conditional approval from FDA to be used for the control of mortality in catfish due to columnaris disease associated with *F. columnare* (FDA 2008).

The U.S. aquaculture community would like to expand the FDA-approved label for Aquaflor to include the therapeutic treatment of all freshwater-reared finfishes at 15 mg FFC·kg$^{-1}$ BW·d$^{-1}$ for 10 d. Some peer-reviewed studies have suggested that 15 mg FFC·kg$^{-1}$ BW·d$^{-1}$ for 10 d controls mortality to a greater extent than 10 mg FFC·kg$^{-1}$ BW·d$^{-1}$ for 10 d. Bowker et al. (2010) found that 10 mg FFC·kg$^{-1}$ BW·d$^{-1}$ effectively controlled mortality in sunshine bass (female white bass *Morone chrysops* × male striped bass *M. saxatilis*) naturally infected with *Streptococcus iniae*. Gaunt et al. (2010a) challenged channel catfish with *F. columnare* and found that 10 mg FFC·kg$^{-1}$ BW·d$^{-1}$ administered for 10 d was efficacious and safe for the control of mortality. Darwish (2007) challenged sunshine bass with *S. iniae* and concluded that the optimum Aquaflor dose for controlling mortality was between 10 and 15 mg FFC·kg$^{-1}$ BW·d$^{-1}$ for 10 d. Finally, Gaunt et al. (2010b) challenged Nile tilapia *Oreochromis niloticus* with *S. iniae* in separate dose-titration and dose-confirmation experiments and concluded that either 10 or 15 mg FFC·kg$^{-1}$ BW·d$^{-1}$ for 10 d will significantly reduce mortality, but that 15 mg FFC·kg$^{-1}$ BW·d$^{-1}$ for 10 d could minimize the potential for any surviving fish to become *S. iniae* carriers. In addition, there have been reports from the Pacific Northwest that administering 10 mg FFC·kg$^{-1}$ BW·d$^{-1}$ for 10 d under certain environmental conditions has not been totally effective to control mortality in salmonids caused by coldwater disease; there is anecdotal evidence that 15 mg FFC·kg$^{-1}$ BW·d$^{-1}$ for 10 d has been more efficacious (D. Erdahl, U.S. Fish and Wildlife Service, personal communication).

To obtain FDA approval of 15 mg FFC·kg$^{-1}$ BW·d$^{-1}$ for 10 d, studies must be conducted to demonstrate this treatment regimen is safe to the target animals. These target-animal safety studies are designed to estimate a margin of safety associated with overdosing and overexposing healthy test fish (e.g., Greenlees 1997; Gaikowski et al. 2003). Sunshine bass are commonly reared at public and private fish culture facilities for sportfishing or food fish purposes and are considered a representative, freshwater-reared, warmwater finfish. The purpose of this study was to evaluate the safety of Aquaflor to sunshine bass when administered in feed at 15 (1× the maximum proposed therapeutic dose), 45 (3×), and 75 (5×) mg FFC·kg$^{-1}$ BW·d$^{-1}$ for 20 d (2× the approved 10-d treatment duration).

## METHODS

Juvenile sunshine bass were obtained from Small Fry Fish Farm (Wilmot, Arkansas) and shipped to the Harry K. Dupree–Stuttgart National Aquaculture Research Center (Stuttgart, Arkansas). The fish were transferred into two, circular, 300-L fiberglass tanks (120 cm diameter × 70 cm deep) and held for 7 d. During the 7-d holding period, well water flow was adjusted to provide one water exchange per hour. Sunshine bass are sexually immature at this size and the male : female ratio was assumed to be 50:50. Fifty fish (25 per reference tank) were arbitrarily collected and measured for total length (11.1 ± 0.4 cm [mean ± SD]) and weight (13.6 ± 1.6 g). Fish were fed a commercially available feed commonly used in sunshine bass production (Silver Cup 3/32 trout pellets; Nelson and Sons, Murray, Utah) at 2% BW·d$^{-1}$ divided equally between the morning and afternoon feedings.

This study was configured in a completely randomized design. Twelve fiberglass study tanks (76 cm diameter × 76 cm deep), each containing 100 L of flow-through well water, were stocked with four groups of five sunshine bass each ($n = 20$); three additional nonstudy tanks were similarly stocked for the purpose of determining proper feeding rates as described below. Water flow provided one exchange per hour and the fish were acclimated to the tanks for 3 d. Study tanks were sequentially numbered and treatments were randomly assigned to three tanks per treatment by using the random number generation analysis tool in Microsoft Excel (Redmond, Washington).

Tanks were aerated to maintain dissolved oxygen (DO) levels at or above 70% saturation. Dissolved oxygen (6.1 ± 0.6 mg·L$^{-1}$) and water temperature (21.9 ± 0.3°C) were monitored daily in each tank with a YSI model 95 meter (YSI Environmental, Yellow Springs, Ohio). Lighting was natural sunlight via skylights. Fish were observed daily for mortality, general behavior, and feeding behavior. An Orion Research 720A Meter (Thermo Electron, Beverly, Massachusetts) was used to measure pH (7.5 ± 0.1); total alkalinity (195 ± 0.8 mg·L$^{-1}$ as $CaCO_3$)

Downloaded by [US Fish & Wildlife Service] at 05:37 29 December 2011

and total hardness (114 ± 0.5 mg·L$^{-1}$ as $CaCO_3$) were measured weekly by titration methods (APHA et al. 2005).

Aquaflor was provided by Intervet/Schering-Plough Animal Health Corporation (Summit, New Jersey). Control and medicated feeds were prepared at the U.S. Fish and Wildlife Service's Aquatic Animal Drug Approval Partnership Program (Bozeman, Montana) in a Marion Mixer (Model SPS-1244; Marion Mixers, Marion, Iowa). Medicated feeds were prepared by top-coating the commercial feed with appropriate amounts of Aquaflor followed by menhaden fish oil (0.5% w:w) to administer doses of 0, 15, 45, and 75 mg FFC·kg$^{-1}$ BW, respectively, when fed at 2% BW·d$^{-1}$; control feed was top-dressed with menhaden fish oil only. Feed samples were collected from each batch of feed to confirm FFC concentration, homogeneity, and stability and to verify that control feed was not contaminated with FFC. Florfenicol concentrations were determined via high-performance liquid chromatography (Hayes 2005) by Eurofins AvTech Laboratories (Portage, Michigan).

There were three replicates of each treatment (12 test tanks) and three nonstudy tanks. Daily rations were weighed up to 7 d in advance into separate containers and stored at 4°C. The study was conducted blind so that only the study director knew the treatment concentrations. Fish in the nonstudy tanks were weighed weekly, and the amount of feed was adjusted for all tanks based on these weights.

Before the start of the study, reference fish were arbitrarily collected ($n = 30$) and used to characterize baseline fish health and histopathology associated with routine fish culture and handling procedures. Necropsy and subsequent bacterial culture (from the anterior kidney on tryptic soy agar media with 5% sheep blood; 48 h incubation at 28°C) were performed on 10 of these fish. Any bacterial growth was presumptively identified. The remaining fish were fixed in Davidson's Solution (Thermo Fisher Scientific, Waltham, Massachusetts) for 48 h and stored in 70% ethanol for subsequent histological examination.

At the end of the study, all fish from each test tank ($n = 20$) were collected, their lengths and weights were determined, and they were euthanized by spinal severance. To assess general fish health, standard necropsy procedures were used to examine external and internal tissues for gross pathologies of all fish. Each fish health evaluation comprised visually examining the skin, gills, and internal organs (liver, spleen, and kidney) for signs of gross lesions or abnormalities. Ten fish from each tank were randomly selected and fixed in Davidson's solution as described above and stored in 70% ethanol for subsequent examination.

*Histology*.—Selected fixed tissues were dissected and processed in Fisher Omnisette tissue cassettes (Fisher Scientific, Fair Lawn, New Jersey). The tissues were infiltrated with paraffin by means of a Leica ASP 300 Advanced Smart Processor (Leica Microsystems, Nussloch, Germany), and the paraffin-infiltrated tissue samples were embedded in paraffin blocks by means of a Leica EG 1160 Tissue Embedding System (Leica Microsystems).

Tissues in selected paraffin blocks were sectioned on a rotary microtome (Leica RM2255 Rotary Microtome; Leica Microsystems). The 5-μm thick tissue sections were mounted on glass microscope slides and stained with hematoxylin and eosin; slides were evaluated microscopically. A histologist documented features associated with histopathologies (e.g., inflammation, edema), whether these were scattered or focused, and whether any were artifacts of tissue dissection, preservation, or processing. According to CVM guidance, 2 of the 10 fish randomly selected from each tank for histological evaluations of gill, liver, anterior kidney, posterior kidney, brain, heart, muscle, skin, spleen, pyloric intestine, and rectal intestine tissues. Histological evaluations of the remaining eight fish were only made for gill, liver, anterior kidney, and posterior kidney tissues.

The tissues were evaluated histologically for evidence of Aquaflor-induced toxicity. Tissues were scored under a 6-point ordinal severity scale: 0 = no change; 1 = normal (<5% of the tissue affected); 2 = mild (5–15% of the tissue affected); 3 = moderate (15–25% of the tissue affected); 4 = marked (25–50% of the tissue affected); 5 = severe (>50% of the tissue affected). Only scores of 4 or 5 were considered severe enough to adversely affect fish health. According to CVM guidance and to minimize the number of histological images needing to be scored, images from the 0- and 75-mg·kg$^{-1}$ treatment groups were evaluated first. If significant differences were not detected between these two groups, then it would be assumed that significant differences would not be detected among the 0- and 15- or 45-mg·kg$^{-1}$ treatment groups, and that histological evaluation of the lower-exposure groups would not be required. Owing to histopathologies detected in kidney tissue of fish from the 75-mg·kg$^{-1}$ treatment group that were not detected in the 0-mg·kg$^{-1}$ treatment group fish, kidneys of fish from the 45-mg·kg$^{-1}$ treatment group were examined.

Mean fish weight and length at the end of the study were analyzed by a one-way analysis of variance (ANOVA; SYSTAT version 12.02; Systat Software, San Jose, California). The treatment effect was tested at $\alpha = 0.05$ significance level.

## RESULTS

There was no mortality in any tank during the study, general behavior was normal, feeding behavior was consistently aggressive, and all feed was consumed within 10 s at every feeding. During the study, mean growth as indicated by increases in length and weight was 1.4 cm and 7.3 g among all fish in the treatment tanks. There were no significant differences in mean length ($P = 0.493$) or mean weight ($P = 0.955$) among the four treatment groups. Total hardness, total alkalinity, and pH were at acceptable levels for sunshine bass culture (Harrell et al. 1990).

The measured mean FFC concentrations for the 15-, 45-, and 75-mg FFC·kg$^{-1}$ BW·d$^{-1}$ treatment groups were 14.5 ± 1.22, 42.6 ± 3.50, and 74.6 ± 8.33 mg FFC·kg$^{-1}$ BW·d$^{-1}$, respectively. These were within 5% of the Aquaflor-medicated

Downloaded by [US Fish & Wildlife Service] at 05:37 29 December 2011

feed target concentrations. There was no FFC detected in the 0-mg·kg$^{-1}$ treatment group (control) feed.

## Fish Health and Histology

*Reference population.*—External and internal tissues appeared normal in the fish subjected to gross necropsy ($n$ = 10). Very low to moderate levels of the ectoparasite *Epistylis* spp. were observed on the gills and skin of nine of these fish, and frayed or eroded fins were found on four of these fish. Bacterial isolation from kidneys of these fish ($n$ = 10) was positive in two fish. Isolates from one fish were presumptively identified as *Staphylococcus* spp. and isolates from the other fish were presumptively identified as *Aeromonas sobria* and *Pseudomonas* spp. (negative for *P. fluorescens*). Only *A. sobria* is considered pathogenic to fish and it is not an obligate pathogen; it is commonly found in apparently healthy fish at low levels (Noga 1996).

In the fish examined histologically ($n$ = 20), no histopathologies were observed in the heart, liver, skin, muscle, posterior kidney, spleen, or pyloric intestine tissues. Moderate or marked epithelial separation of gill tissue was observed in all these fish. Although histopathologies were observed in all other tissues examined, they did not appear sufficient to adversely affect the health of the fish.

*0-mg FFC·kg$^{-1}$ BW·d$^{-1}$ treatment group (control).*—All fish appeared healthy at the end of the study ($n$ = 60). Necropsies performed on all of these fish detected no gross external or internal lesions and no *Epistylis* spp. were observed. However, one or two yellow grub *Clinostomum marginatum* endoparasites were observed in 17% of the fish. Eroded or frayed fins were found in 8% of the fish, minor diffuse hemorrhages were observed on the skin of 2% of the fish, and an opaque eye lens was observed in 7% of these fish. No histopathologies were observed in heart, liver, or rectal intestine, and no inflammation was observed in the pyloric intestine. Histological observations of mild to moderate changes are presented in Table 1. Mild to moderate epithelial lifting of gill tissue (Figure 1) was observed in 97% of the samples. Moderate to marked vacuolation of neurons (Figure 2) was observed in all brain tissue samples. No histopathologies were observed in other tissues that were considered severe enough to affect the health of the fish.

*15-mg FFC·kg$^{-1}$ BW·d$^{-1}$ treatment group.*—All fish appeared healthy ($n$ = 60) and gross necropsies indicated that external and internal organs were normal at the end of the study. No *Epistylis* spp. were found on gills or skin, but a few yellow grubs were observed in 18% of the fish. Eroded or frayed fins were found on 3% of the fish, minor diffuse hemorrhages were observed on the skin of 10% of the fish, and liver hemorrhage was observed in 3% of the fish. No tissues from fish in this treatment were examined histologically.

*45-mg FFC·kg$^{-1}$ BW·d$^{-1}$ treatment group.*—All fish in this treatment group appeared healthy ($n$ = 60) and gross necropsies of external and internal organs indicated that they were normal at the end of the study. No *Epistylis* spp. were observed on the gills or skin, but a few yellow grubs were observed in 7% of the fish. No eroded or frayed fins and no areas of skin hemorrhages were evident in these fish. An opaque eye lens was observed in 8% and liver hemorrhage was observed in 2% of these fish. No marked or severe histopathologies were noted in the histological sections of kidney tissue (Table 1).

*75-mg FFC·kg$^{-1}$ BW·d$^{-1}$ treatment group.*—All fish in this treatment group appeared healthy ($n$ = 60) and gross necropsies of external and internal organs indicated that the fish were

TABLE 1. Histology findings of tissue samples of sunshine bass fed Aquaflor-medicated feed. Histologies of tissues were not done in the 15-mg FFC·kg$^{-1}$ BW·d$^{-1}$ treatment group. Brain pathologies ($n$ = 6 per treatment) for vacuolation of nerve fibers scored moderate to marked (25–50% of the tissue affected) in almost all samples, but these are common tissue artifacts induced during sample collection. The abbreviation NA = not applicable; these tissues were not examined.

| Tissue and histopathology | Sample size | Treatment (mg FFC·kg$^{-1}$ BW·d$^{-1}$) | | |
|---|---|---|---|---|
| | | 0 | 45 | 75 |
| Heart | 6 | 0 | NA | 0 |
| Muscle, degeneration of fibers | 6 | 33.3% | NA | 66.7% |
| Skin, degeneration | 6 | 16.7% | NA | 0 |
| Spleen, melanomacrophage centers | 6 | 100% | NA | 83.3% |
| Spleen, inflammation | 6 | 16.7% | NA | 0 |
| Pyloric intestine, degeneration of mucosal epithelium | 6 | 33.3% | NA | 16.7% |
| Pyloric intestine, necrosis of mucosal epithelium | 6 | 33.3% | NA | 16.7% |
| Pyloric intestine, inflammation | 6 | 0 | NA | 16.7% |
| Rectal intestine, degeneration of mucosal epithelium | 6 | 0 | NA | 0 |
| Rectal intestine, necrosis of mucosal epithelium | 6 | 0 | NA | 0 |
| Gill, epithelial lifting | 30 | 96.7% | NA | 100% |
| Gill, proliferation | 30 | 3.3% | NA | 6.7% |
| Gill, telangectiasis | 30 | 66.7% | NA | 46.7% |
| Gill, inflammation | 30 | 93.3% | NA | 83.3% |
| Liver | 30 | 0 | NA | 0 |
| Anterior kidney, melanomacrophage centers | 30 | 13.3% | 0 | 3.3% |
| Posterior kidney, degeneration of tubule epithelium | 30 | 100% | 100 | 100% |
| Posterior kidney, necrosis of tubule epithelium | 30 | 96.6% | 100 | 100% |
| Posterior kidney, inflammation | 30 | 3.3% | 0 | 0 |

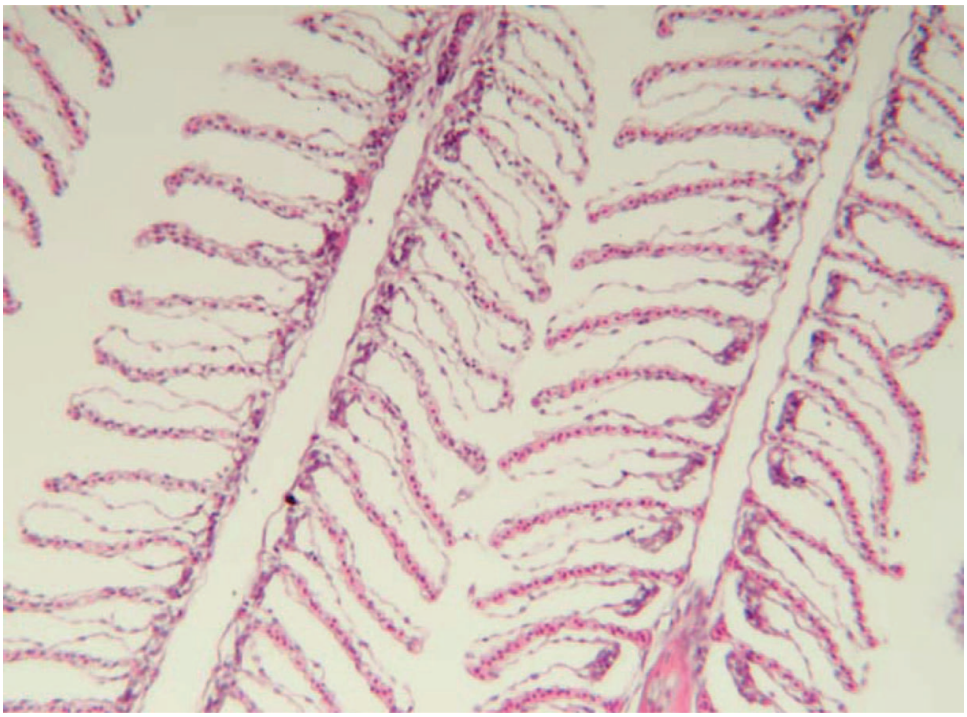

FIGURE 1. Separation of gill epithelium from lamellae (epithelial lifting) without edema in juvenile sunshine bass. [Figure available in color online.]

normal at the end of the study. No *Epistylis* spp. were observed on the gills or skin of any fish, but a few yellow grubs were observed in 10% of the fish. Eroded or frayed fins were found on 5% of the fish, skin hemorrhages were observed on 3% of the fish, an opaque eye lens was observed in 2% of the fish, and liver hemorrhages were observed in 5% of the fish. No histopathologies were observed in the heart or rectal intestine tissues, or in the liver. Histological observations of mild to moderate changes are presented in Table 1. No degeneration of skin was observed, and no inflammation was observed in the posterior kidney or spleen.

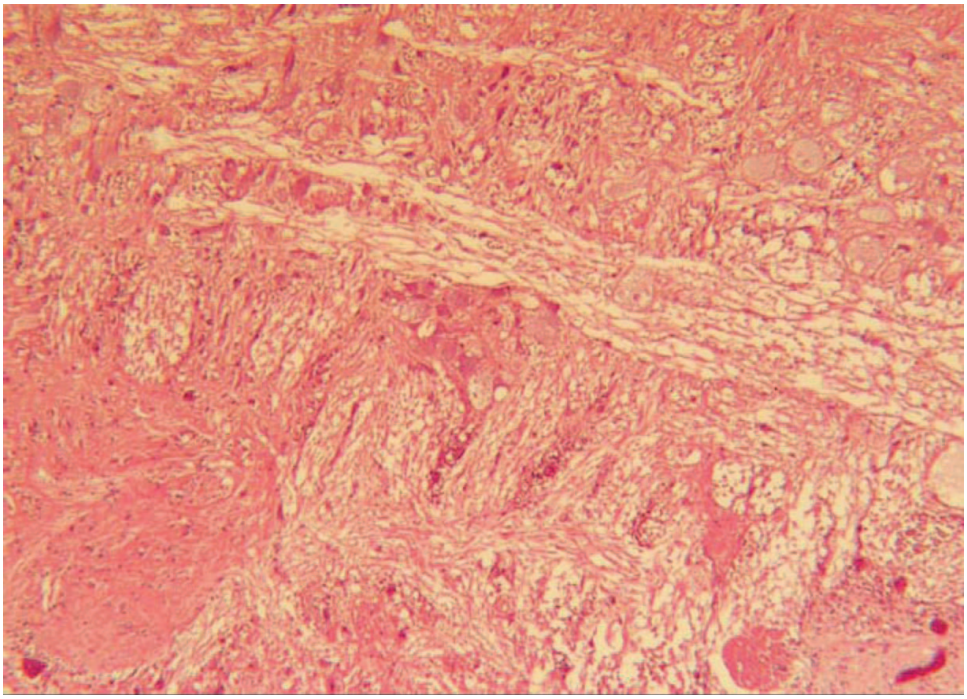

FIGURE 2. Vacuolation (white spaces) of brain tissue in juvenile sunshine bass. [Figure available in color online.]

Downloaded by [US Fish & Wildlife Service] at 05:37 29 December 2011

Moderate to marked vacuolation of neurons was observed in brain tissue of five fish ($n = 6$). Although histopathologies were observed in all other tissues examined, they were not considered severe enough to affect the health of the fish.

## DISCUSSION

Based on fish survival, the aggressive nature displayed when feeding, and normal behavior, Aquaflor-medicated feed at a dose of 75 mg FFC·kg$^{-1}$ BW·d$^{-1}$ for 20 d is safe for fingerling sunshine bass. Such conclusions are consistent with those found in similar studies to evaluate the safety of Aquaflor administered in feed to other fishes. In a study conducted by Gaikowski et al. (2003) on fingerling channel catfish, there was no mortality, fish behavior was normal, and minimal pathology findings were reported. In a study conducted by Inglis et al. (1991), histological changes were not observed in the kidneys of Atlantic salmon parr at doses up to 100 mg FFC·kg$^{-1}$ BW·d$^{-1}$ for 10 d. Results from a study recently completed on yellow perch *Perca flavescens* to evaluate the safety of 15, 45, and 75 mg FFC·kg$^{-1}$ BW·d$^{-1}$ for 20 d (J. D. Bowker, unpublished results) were similar to those observed in the present study. That study on yellow perch followed a research protocol that was nearly identical to that of the present study; a significant difference was not detected in mean cumulative mortality between exposure groups and histological findings were unremarkable.

The findings from the histological examinations in the present study were also unremarkable. Tissue sections of individual fish were so similar that the treatment groups were nearly indistinguishable. The marked brain pathologies observed (25–50% of the tissue affected) in tissue from one fish from the reference population and two fish from the 0-mg·kg$^{-1}$ treatment group suggest that exposure to Aquaflor was probably not the cause of the single marked pathology in the 75-mg·kg$^{-1}$ treatment group. These changes were most probably an artifact and not a pathological response to the medication.

The results of the present study illustrate the sensitivity of tissues to sample preparation and the potential for confusing artifact with pathology. Routine methods of specimen preparation can subject tissues to artifacts such as tissue shrinkage, particularly if processing is delayed. Tissues must be immersed in the fixative as quickly as possible or these artifacts can form. This is especially true for gill tissues, which may exhibit epithelial swelling and separation from the basal membrane if collection and transfer to fixative takes more than 2 min to complete (Ferguson 1989). The lack of proteinaceous fluid in the gills of fish in the present study implies that epithelial separation was an artifact of collection procedures (i.e., tank removal, anesthesia, necropsy, and fixation) and not due to treatment with FFC. Vacuolation, a common artifact of processing and handling, can be mistaken for spongiosis in sections of brain tissue (Ferguson 1989). Thorough gross necropsy and dissection in the present study did not always allow for quick processing; therefore, it is likely that some artifacts were introduced by the variable sample collection and preparation procedures (approximately 2–4 min).

The yellow grub is a common endoparasite in North America and is found imbedded intramuscularly or subcutaneously in many fish species, including *Morone* spp. (Mitchell 1995; Hoffman 1999). These parasites are readily visible to the unaided eye but are relatively harmless unless the fish are heavily infested. The absence of yellow grubs in the reference fish of the present study suggests infestation occurred just before the study took place, and the trematode may still have been in the migration stage but not yet fully encysted and readily observed.

In summary, no mortality and no dose-related effect on general fish behavior or feeding behavior was observed in juvenile sunshine bass. Fish consumed 100% of feed regardless of the concentration of FFC in the feed, and no dose-related effect was detected on fish growth. No Aquaflor-related histopathologies were detected in any fish from the 0- and 75-mg·kg$^{-1}$ treatments. Therefore, the margin of safety of Aquaflor-medicated feed to sunshine bass extends to at least 75 mg FFC·kg$^{-1}$ BW·d$^{-1}$, or 5× the proposed treatment concentration of 15 mg FFC·kg$^{-1}$ BW·d$^{-1}$, when administered for 20 consecutive days, or twice the proposed treatment period. Before treating fish with a higher dose of Aquaflor-medicated feed (e.g., 15 mg FFC·kg$^{-1}$ BW·d$^{-1}$), a cost–benefit analysis should be completed to determine whether the potential of increasing survival warrants the increased cost to purchase the antibiotic and manufacture the medicated feed. For example, a 10-d Aquaflor-medicated feed treatment of 100,000 sunshine bass fingerlings fed at 1% BW·d$^{-1}$ would cost approximately US$500 for 10 mg FFC·kg$^{-1}$ BW·d$^{-1}$ and $650 for 15 mg FFC·kg $^{-1}$BW·d$^{-1}$ (C. Nelson, Silver Cup Fish Feed, personal communication). End users should also consider that administering antibiotic doses that are less than effective may increase the chances of development of bacterial resistance.

## ACKNOWLEDGMENTS

We thank Intervet/Schering-Plough Animal Health Corporation for supplying the Aquaflor for the study. Cindy Ledbetter (SNARC) set up the experiment and took care of the daily activities, and Miranda Dotson (AADAP) prepared samples for histological observation. Roy Yanong, Pat Gaunt, Maren Tuttle-Lau, Ahmed Darwish, and Jesse Trushenski provided critical reviews of the manuscript. Mention of trade names or commercial products in this article is solely for the purpose of providing specific information and does not imply recommendation or endorsement by the U.S. Department of Agriculture or the U.S Fish and Wildlife Service.

## REFERENCES

APHA (American Public Health Association), American Water Works Association, and Water Pollution Control Federation. 2005. Standard methods for the examination of water and wastewater, 21st edition. APHA, Washington, D.C.

Downloaded by [US Fish & Wildlife Service] at 05:37 29 December 2011

Alderman, D. J. 1988. Fisheries chemotherapy: a review. Pages 1–61 *in* J. F. Muir and R. J. Roberts, editors. Recent advances in aquaculture, volume 3. Croom Helm, London, UK.

Bjorndal, T. 1990. The economics of salmon aquaculture. Blackwell Scientific Publications, Oxford, UK.

Bowker, J. D., V. E. Ostland, D. Carty, and M. P. Bowman. 2010. Effectiveness of Aquaflor (50% florfenicol) to control mortality associated with *Streptococcus iniae* in freshwater-reared, subadult sunshine bass. Journal of Aquatic Animal Health 22:254–265.

Clarke, R., and D. Scott. 1989. An overview of world salmon production and recent technology developments. Bulletin of the Aquaculture Association of Canada 89:31–38.

Darwish, A. M. 2007. Laboratory efficacy of florfenicol against *Streptococcus iniae* infection of sunshine bass. Journal of Aquatic Animal Health 19:1–7.

FDA (Federal Drug Administration). 2008. Approved drugs for use in aquaculture. FDA, Washington, D.C. Available: www.fda.gov/downloads/AnimalVeterinary/ResourcesforYou/AnimalHealthLiteracy/UCM109808.pdf. (September 2010).

Ferguson, H. W. 1989. Systemic pathology of fish: a text and atlas of comparative tissue responses in diseases of teleosts. Iowa State University Press, Ames.

Frerichs, G. N., and R. J. Roberts. 1989. The bacteriology of teleosts. Pages 289–319 *in* R. J. Roberts, editor. Fish pathology, 2nd edition. Balliere Tindall, London, UK.

Fukui, H., Y. Fujihara, and T. Kano. 1987. In vitro and in vivo antibacterial activities of florfenicol, a new fluorinated analog of thiamphenicol, against fish pathogens. Fish Pathology 22:201–207.

Gaikowski, M. P., J. C. Wolf, R. G. Endris, and W. H. Gingerich. 2003. Safety of Aquaflor (florfenicol, 50% type A medicated article), administered in feed to channel catfish, *Ictalurus punctatus*. Toxicologic Pathology 31: 689–697.

Gaunt, P. S., R. Endris, A. McGinnis, W. Baumgartner, A. Camus, J. Steadman, D. Sweeney, and F. Sun. 2010a. Determination of florfenicol dose rate in feed for control of mortality in Nile tilapia infected with *Streptococcus iniae*. Journal of Aquatic Animal Health 22:158–166.

Gaunt, P. S., D. Gao, F. Sun, and R. Endris. 2010b. Efficacy of florfenicol for control of mortality caused by *Flavobacterium columnare* infection in channel catfish. Journal of Aquatic Animal Health 22:115–122.

Greenlees, K. J. 1997. Laboratory studies for the approval of aquaculture drugs. Progressive Fish-Culturist 59:141–148.

Harrell, R. M., J. H. Kerby, and R. V. Minton. 1990. Culture and propagation of striped bass and its hybrids. American Fisheries Society, Southern Division, Striped Bass Committee, Bethesda, Maryland.

Hayes, J. M. 2005. Determination of florfenicol in fish feed by liquid chromatography. Journal of the Association of Official Analytical Chemists 88:1777–1783.

Hoffman, G. L. 1999. Parasites of North American freshwater fishes, 2nd edition. Comstock Publishing Associates, Cornell University Press, Ithaca, New York.

Horsberg, T. E., K. A. Hoff, and R. Nordmo. 1996. Pharmacokinetics of florfenicol and its metabolite florfenicol amine in Atlantic salmon. Journal of Aquatic Animal Health 8:292–301.

Inglis, V., R. H. Richards, K. J. Varma, I. H. Sutherland, and E. S. Brokken. 1991. Florfenicol in Atlantic salmon, *Salmo salar* L, parr: tolerance assessment of efficacy against furunculosis. Journal of Fish Disease 14:343–351.

Klontz, G. W. 1987. Control of bacterial diseases in salmonids. Salmonid 11(3):5–13.

Mitchell, A. J. 1995. Importance of treatment duration for praziquantel used against larval digenetic trematodes in sunshine bass. Journal of Aquatic Animal Health 7:327–330.

Noga, E. J. 1996. Fish disease: diagnosis and treatment. Mosby-Year Book, St. Louis, Missouri.

Nordmo, R., K. J. Varma, I. H. Sutherland, and E. S. Brokken. 1994. Florfenicol in Atlantic salmon, *Salmo salar* L.: field evaluation of efficacy against furunculosis in Norway. Journal of Fish Diseases 17:239–244.

Samuelsen, O. B., B. Hjeltnes, and J. Glette. 1998. Efficacy of orally administered florfenicol in the treatment of furunculosis in Atlantic salmon. Journal of Aquatic Animal Health 10:56–61.

Yasunaga, N., and S. Yasumoto. 1988. Therapeutic effect of florfenicol on experimentally induced pseudotuberculosis in yellowtail. Fish Pathology 23:1–5.

Downloaded by [US Fish & Wildlife Service] at 05:37 29 December 2011