U.S. Fish & Wildlife Service

California Nevada Fish Health Center

FY2009 Technical Report: Health and energy evaluation of juvenile fish from Link R. trap and haul project and J-canal salvage.

J.Scott Foott*, R. Stone and R. Fogerty

U.S. Fish and Wildlife Service
California-Nevada Fish Health Center
24411 Coleman Hatchery Road
Anderson, CA 96007
PH: (530) 365-4271 FAX: (530) 365-7150
May 2010

Summary:

Juvenile suckers, chubs, and fathead minnows were collected from a rotary screw trap downstream of Link River dam between 14July and 9September 2009. Fish were examined for external signs of disease and injury as well as sampled for laboratory analysis (histology, tissue imprints, protein and triglyceride content). All species had a high incidence of parasitic infection but relatively few fish showed overt signs of disease. Post-capture survival of juvenile suckers was likely reduced due to injury associated with the trapping operation. Growth and triglyceride levels were relatively static through the summer in all 3 species. Histological examination of 25 juvenile suckers collected in a December 2009 J-canal salvage revealed similar parasite infections (at lower prevalence) as the Link R. samples but no signs of overt disease. Excluding capture injury at the Link R. rotary screw trap, juvenile suckers were deemed fit enough to survive salvage operations.

The correct citation for this report:

Foott J.S, R. Stone, and R. Fogerty. 2010. FY2009 Technical Report: Health and energy evaluation of juvenile fish from Link R. trap and haul project and J-canal salvage. U.S. Fish & Wildlife Service California – Nevada Fish Health Center, Anderson, CA. http://www.fws.gov/canvfhc/reports.asp

Notice
The mention of trade names or commercial products in this report does not constitute endorsement or recommendation for use by the Federal government. The findings and conclusions in this article are those of the authors and do not necessarily represent the views of the US Fish and Wildlife Service.

Background – Both Lost River Sucker (*Deltistes luxatus*) and Shortnose Sucker (*Chasmistes brevirostris*) of Upper Klamath Lake, Oregon are listed as endangered species (U.S. Fish and Wildlife Service, 1988). Under a 2008 biological opinion, Reclamation conducted a juvenile sucker trap and haul effort during July - September 2009 downstream of Link River dam (Wilkens 2010). The California-Nevada Fish Health Center was contracted by Reclamation to evaluate the health and energy status of juvenile suckers, chubs, and fathead minnows captured during the trap and haul operation as well as juvenile suckers salvaged in the fall from J-canal. Health evaluation was prompted by the high incidence of sucker mortality that occurred in a 2008 Link River trapping study (Marine and Lappe 2009) as well as previous pathogen sampling by the Fish Health Center (Foott et al.2007a). The addition of juvenile chub and fathead minnow to the sucker study was to ensure adequate sample size for energy evaluations throughout the summer trapping effort. General health and condition evaluation is necessary to assess the survival probability of salvaged suckers.

Methods

Collection

Fish were collected from a 1.5 m rotary screw trap approximately 250m downstream of Link R. dam on 5 occasions (14-15July, 27-28July, 11-12August, 25-26August, and 9September). After an overnight fishing period, all fish were removed from the live box, sorted to species (or type, e.g chub or sucker), and the first 100 – 150 of a given fish species (type) examined for external signs of trauma or infection (Table 1). Water quality measurements (temperature, pH, dissolved oxygen) were taken when the live box was first opened in the morning. Weak or moribund fish were selected first for specific laboratory samples and 12 normal appearing fish frozen for energy assays. Laboratory samples included tissue imprints from suspected *Flavobacterium columnare* lesions of the gill or skin and kidney imprints from fish with petechial hemorrhage on skin or fin base (suggestive of systemic bacterial infection). These uniquely identified imprints were later gram-stained and examined for the appropriate bacteria (*F. columnare* = filamentous gram-negative rods, kidney imprints = gram-negative rods or gram-positive cocci). Fish showing pale gills or deemed moribund without obvious signs were fixed for histological examination. Typically, a total of 10 – 15 fish per species were fixed for histological evaluation of parasite infection and tissue abnormalities. All imprint slides and histology tubes were uniquely numbered to identify specific fish.

Table 1. External examination criteria recorded for each fish.

Moribund - sample given histology number
Pale gill – sample given histology number
Columnaris lesion – sample given imprint number
Hemorrhage on skin or fin base – sample given imprint number
Attached *Lernaea*
Black spot on skin (metacercaria)
>10% of body de-scaled
Signs of trauma on skin or fins (laceration, bruising)
Eye occlusion
Short operculum

Histological samples were held in Davidson's fixative for 48h, processed for 5µm paraffin sagittal sections, and stained with hematoxylin and eosin. Tissues examined microscopically included skin, muscle, gill, thymus, olfactory pit, eye, brain, liver, intestine, adipose tissue, acinar cells, kidney, and the peritoneal cavity. Fish larger than 70mm were dissected and specific organs processed for histology (kidney, gastrointestinal tract, gill, liver, brain).

Energy assay

Cold distilled water was added to a 20 mL tube containing the fish (1:1 w / v) and blended for 30 – 90s with a Biospec M133 homogenizer. Two aliquots (100-200µl) of the homogenate (2xWB) were placed into tared 2mL centrifuge tubes, weighed to the nearest 0.01g to determine tissue weight (homogenate wt. divided by 2), and assayed for triglyceride and protein.

Triglyceride – Tissue triglyceride content (mg TG / g tissue) was assayed by a modification of Weber et al. 2003. Absolute isopropanol was added (5x dilution w/v) to an aliquot of homogenate, mixed at room temperature for 20 min, centrifuged at 3220xg for 5 min, and replicate 10 µL samples of the 10x diluted supernatant used in an enzyme assay for triglyceride (Pointe Scientific triglyceride GPO kit). Standards were diluted in a 1:4 mixture of distilled water and isopropanol (same as blank solution).

Protein - Protein content (mg protein / g tissue) of the homogenate was assayed by a modification of the alkaline digestion method reported by Woo et al. 1978. Briefly, 0.5N NaOH was added to the homogenate (5x dilution w/v), mixed at 45°C for 120 min, centrifuged at 3220xg for 5 min, and replicate 10 µL samples of the 10x diluted supernatant assayed for total protein by the Biuret method (Pierce BCA protein assay kit, Rockford IL). The blank consisted of 1:4 mixture of distilled water and 0.5N NaOH. Albumin diluted in the blank was used as the protein standard.

Statistical analysis - Analysis was performed with SigmaStat 3.1 software on raw data. Normality was tested by the Kolmogorov – Smirnov method at the P= 0.05 level. One-way ANOVA or T-test (data with normal distribution, reported with F or t value) or Kruskal-Wallace ANOVA or Mann-Whitney U test on ranks (non-parametric analysis) with subsequent multiple comparison procedures (Holm-Sidak or Dunns method respectively, alpha $\leq$ 0.05) was used to compare groups.

Results:

The trap was sampled in the morning with water temperatures generally above 20°C (Table 2). Alkaline pH ($\geq$ 9.7) occurred in August and September.

Table 2. Water quality parameters at time of sampling.

	time	temp	D.O.	pH
14-Jul	11:05	21.7	7.8	9.49
27-Jul	7:40	23.2	7.3	8.08
11-Aug	8:00	21.0	7.9	9.70
25-Aug	9:00	20.6	8.2	9.83
9-Sep	8:30	16.5	8.6	9.78

Suckers - A total of 129 juvenile suckers (not identified to species) were examined from the Link R. trap between 14July and 09 September. As in previous years, juvenile sucker catch dropped to low numbers (2) by September. Twenty five juvenile suckers, collected during an electrofishing salvage effort in J-Canal (30Nov – 03Dec), were sampled exclusively for histological examination.

A moderate increase in standard length was observed in the 10 to 12 fish energy assay sub-sample between 14July and 25August (Table 3). Weight and condition factor did not change significantly after 27July. Low sample number (2) in September limits trend analysis past the 25August sample. Whole body protein and triglyceride concentrations remained similar throughout the summer as did condition factor (KSL). Triglyceride levels were similar to mean concentrations reported for juveniles captured in A-canal during July (4 mg/g) and August (6 mg/g) of 2005 (Foott et al. 2007b).

Injury (trauma and de-scaling) was seen in 14 -39% of the catch and more prevalent in suckers than either chub or Fathead minnows (Table 4). It is likely that sucker behavior (bottom-orientation) and limited swimming ability in the turbulent conditions of the live box resulted in injury. Short opercula were observed in 11 – 22% of the collection groups however its significance to fitness is unknown. The prevalence of *Lernaea* infestation increased over the summer and ranged from 14% on 27July to 58% on 25August. Swollen tissue and moderate hemorrhage at the attachment site was occasionally observed in the infected fish. Lesions, associated with bacterial infection (columnaris ulcers or petechial hemorrhage on the skin), were seen in $\leq$ 11% of the catch. There was poor correlation of external observations and appropriate bacteria detected in the lesion or kidney imprints

(Table 4). It appears that overt bacterial disease was not a significant issue for the out-migrant suckers.

A number of external and internal parasites were seen in histological tissue sections from 41 juveniles (Table 5). The most common external parasite was the cilate *Trichodina* sp. (63% incidence in gill) and often seen in large numbers along gill and olfactory epithelium (Fig. 1). Despite the high incidence and intensity of infection, gill hyperplasia was not often observed in the sections. It is unclear if Trichodina infection is a significant health issue for Upper Klamath Lake fish. Encysted metacercaria (black spot) were seen grossly in only 3% (2 of 129) of fish but in 28% of the histological sections (Fig 2). Generally, only minor inflammation was associated with the cysts. A presumptive *Myxobolus* sp. infection was seen in the intestinal lamina propria layer (22% incidence) however a disease state was not evident (Fig. 3). An unidentified myxosporean trophozoite stage was seen within kidney tubules in 37% of the sections but was not associated with any lesion. No spore stages were seen to aid in its genus identification. Fifteen percent of the liver sections contained hepatocytes with eosinophilic inclusions suggestive of protein droplets (similar to FHM in Fig. 9). Hepatocytes demonstrated little to no glycogen or fat vacuolization during the summer (Fig 4). Only one liver section had necrotic changes suggestive of bacterial infection (multifocal liquefactive necrosis).

J-canal salvage fish -The large size of the savaged suckers (>70 mm FL) required dissection of individual organs for histological examination and largely precluded examination of muscle, eye, olfactory epithelium, and skin. Incidental observations include one metacercarial cyst (black spot) in one of two muscle sections and a *Lernaea* holdfast associated with adipose tissue of one sucker. The 6% incidence of *Trichodina* infection was much lower than summer sample groups (Table 6). In contrast to summer collections, 24 salvage fish had hepatocyte vacuolation suggestive of glycogen deposition (Fig. 4). Heart (19 specimens), brain (15 specimens) and acinar tissue (25 specimens) were normal. Overall, the 25 juveniles collected from J-canal had similar parasites as Link R. suckers and appeared to relatively healthy.

Table 3.
Sucker standard length (SL, mm), weight (WT, 0.1g), condition factor (KSL= Wt / SL^3*10^5), triglyceride (TG mg / g fish), and protein (PRO mg / g fish). Data recorded as mean (SEM), range and number of fish (N) in sample. Letters in common indicate that the differences were not significant (P<0.05).

	14-15JUL	27-28JUL	11-12AUG	25-26AUG	9 SEP
SL	38 (1) a 32 - 45 N=12	50 (1) b 44 - 55 N=12	58 (2) c 50 - 64 N=12	55 (2) bc 50 - 67 N=10	64 (5) c 59 & 68 N=2
WT	0.73 (0.06) a 0.41 – 1.06	1.65 (0.10) ab 1.18 – 2.30	2.69 (0.20) b 1.78 – 2.63	2.37 (0.21) b 1.54 – 2.27	4.04 (0.85) b 3.2 & 4.89
KSL	1.32 (0.03)a 1.16 – 1.49	1.30 (0.02)a 1.20 – 1.47	1.37 (0.06)a 1.15 – 1.78	1.41 (0.05)a 1.15 – 1.66	1.56 (0.00)a 1.55 & 1.58
TG	6.4 (0.3)a 4.5 – 8.9	7.1 (0.6)a 4.4 – 10.8	10.2 (0.9)a 6.9 – 15.6	7.6 (0.5)a 6.3 – 10.6	15.1 (6.2)a 8.9 & 21.3
PRO	54.9 (1.7)a 46.8 – 61.3	60.6 (2.4)a 51.2 – 73.4	47.6 (1.1)a 42.0 – 54.3	49.7 (3.2)a 43.0 – 75.9	65.9 (1.5)a 64.4 & 67.4

Table 4.
Sucker external observations (number of fish with sign, % of total examined, external signs at ≥ 10% highlighted in bold font). Total fish examined = N, moribund without external sign = MB, pale gill = PG, columnaris lesion = FC and number lesion imprints with filamentous gram-negative rods, petechial hemorrhages at fin base / skin = HM and number of d kidney imprints with gram-negative rods, Trauma = TR, ≥ 10% scale loss = DS, *Lernaea* attached = LR, metacercaria black spot = BS, lamprey wound = LP, missing eye = ME, short opercule = SO, abnormal spinal curvature = SC.

	14-15JUL	27-28JUL	11-12AUG	25-26AUG	9 SEP
N	44	28	36	19	2
MB	1 (2.3%)	0	0	0	0
PG	2 (4.5%)	0	1 (2.8%)	0	0
FC F-GNR	2 (4.5%) 1 / 2	0	0	1 (5.3%) 0 / 1	0
HM GNR	0	2 (7.1%) 1 / 2	2 (5.6%) nd	**2 (10.5%)** 1 / 2	0
TR	Nd	**10 (35.7%)**	**5 (13.9%**	**4 (21.0%)**	0
DS	**8 (18.2%)**	**11 (39.3%)**	0	0	0
LR	0	**4 (14.3%)**	**7 (19.4%)**	**11 (57.9%)**	0
BS	2 (4.5%)	0	0	**2 (10.5%)**	0
LP	1 (2.3%)	0	1 (2.8%)	0	0
ME	0	0	0	0	0
SO	**5 (11.4%)**	**6 (21.4%)**	**8 (22.2%)**	**2 (10.5%)**	0
SC	4 (9.1%)	0	0	0	0

Nd not done

Table 5.
Histological observations common to most sucker collection groups. Data reported as number of tissues with condition or parasite / total tissues examined (%) and the incidence of infection observed over all collection groups (Incidence). No histological samples collected on 9Sep. Not all tissues examined from each fish.

	Incidence	14-15JUL	27-28JUL	11-12AUG	25-26AUG
Gill *Trichodina*	**25 / 40 (63%)**	5/ 13 (38%)	8 / 12 (67%)	8 / 10 (80%)	4 / 5 (80%)
Muscle metacercaria Cyst (blackspot	**5 / 18 ** (28%)**	1/ 13 (8%)	3 / 4 ** (75%)	ND**	1 / 1 **
Kidney tubule Myxozoan trophozite	**15 / 41 (37%)**	4 / 13 (31%)	6 / 12 (50%)	3 / 10 (30%)	2 / 6 (33%)
Intestine Myxozoan cyst	**9 / 41 (22%)**	0 / 13 (0%)	5 / 12 (42%)	4 / 10 (40%)	0 / 6 (0%)
Helminth*	**9 / 41 (22%)**	1 / 13 (8%)	3 / 12 (25%)	2 / 10 (20%)	3 / 6 (50%)
Liver eosinophilic hepatocyte inclusions	**5 / 33 (15%)**	2 / 5 (40%)	0 / 12 (0%)	1 / 10 (10%)	2 / 6 (33%)
Inflammation within peritoneum / adipose tissue	**9 / 28** (32%)**	1 / 13 (8%)	1 / 7 (14%)	7 / 8 (88%)	ND**

* Helminth include trematode, cestode, and nematode

** Fish larger than 70mm dissected for individual organ precluding examination of muscle, eye, olfactory epithelium, skin, and bone. Incidence is biased.

Figure 1. Sucker buccal cavity with *Trichodina sp.*

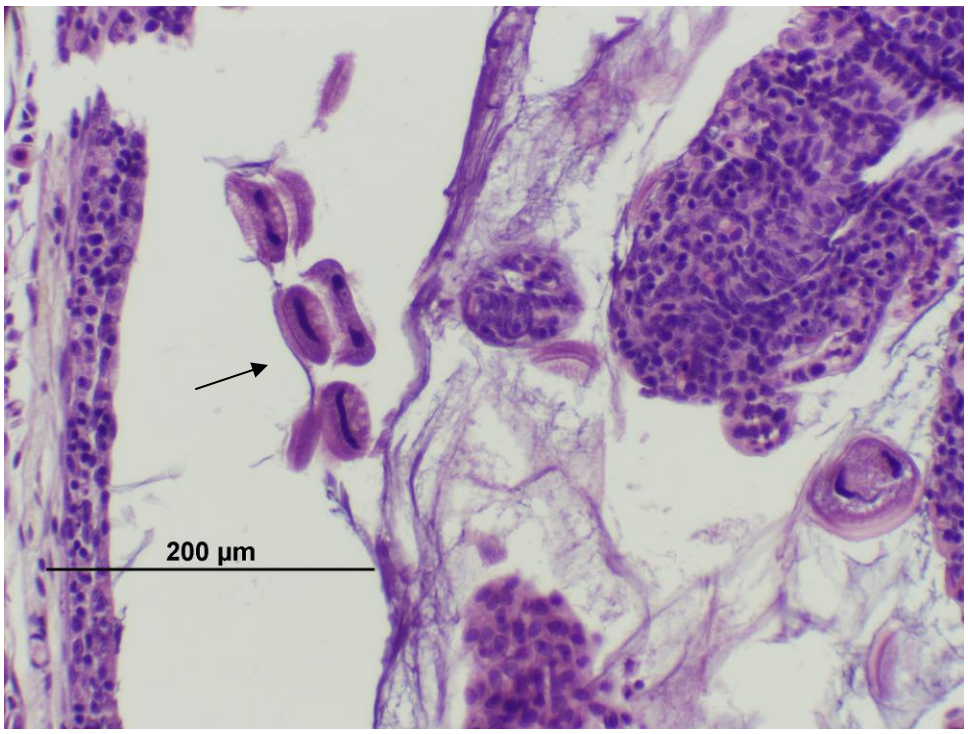

Figure 2. Metacercarial cyst in sucker muscle. Note inflammation around cyst (oval).

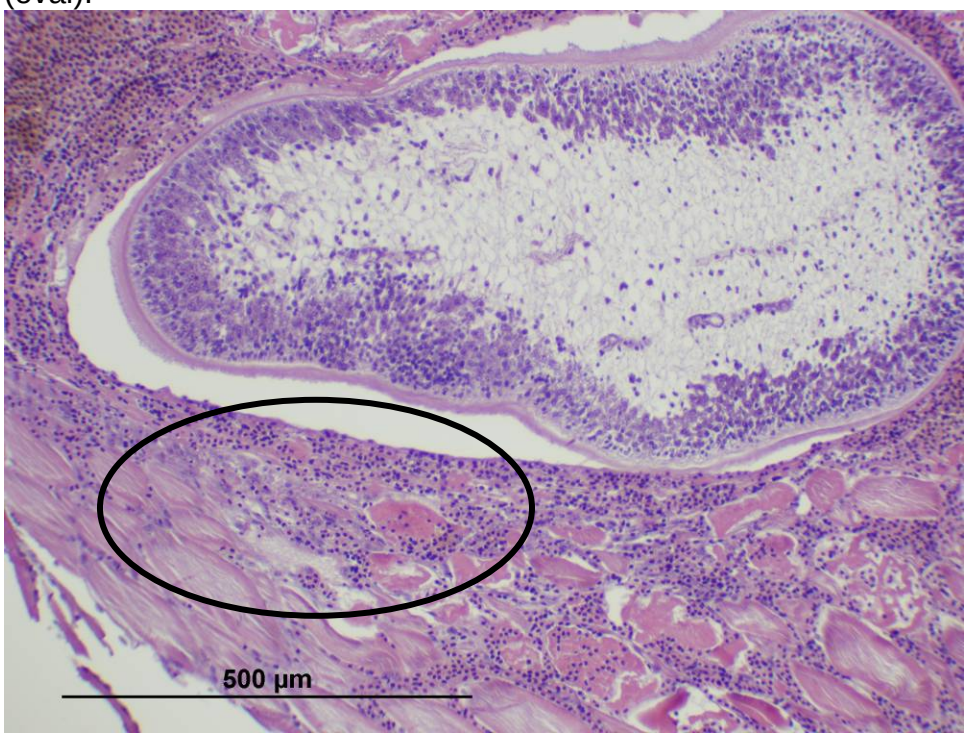

Figure. 3. *Myxobolus* sp. cysts in lamina propria layer of sucker intestine (low and high power).

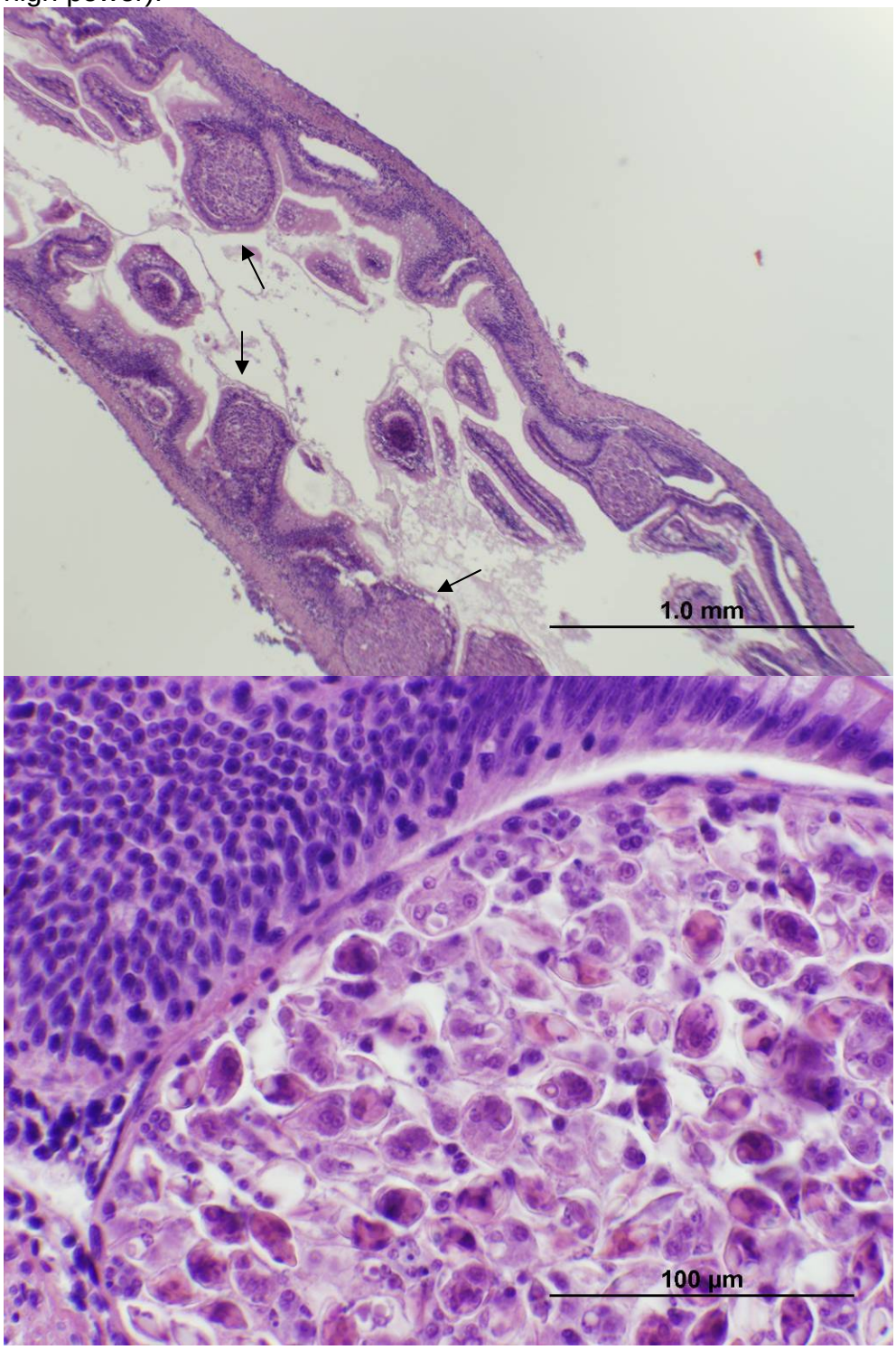

Table 6.
Histological examination results of juvenile suckers collected from J-canal (30Nov-03Dec 2009) and sampled on 04December.

Gill *Trichodina* Epitheliocystis Trematode	 1 / 18 (6%) 2 / 18 (11%) 1 /18 (6%)
Kidney (tubules) Myxozoan trophozoite Hydropic degeneration	 3 / 25 (12%) 2 / 25 (8%)
Intestine Myxozoan cyst Trematode	 1 / 25 (4%) 1 / 25 (4%)
Adipose tissue Inflammatory cell	 2/ 25 (8%)
Eye Trematode	 1 / 13 (8%)

Figure 4. Liver of Link R. (top) and J-canal sucker (bottom). Note trematode within intestine of Link R. fish and degree of vacuolation in J-canal fish (presumptive glycogen).

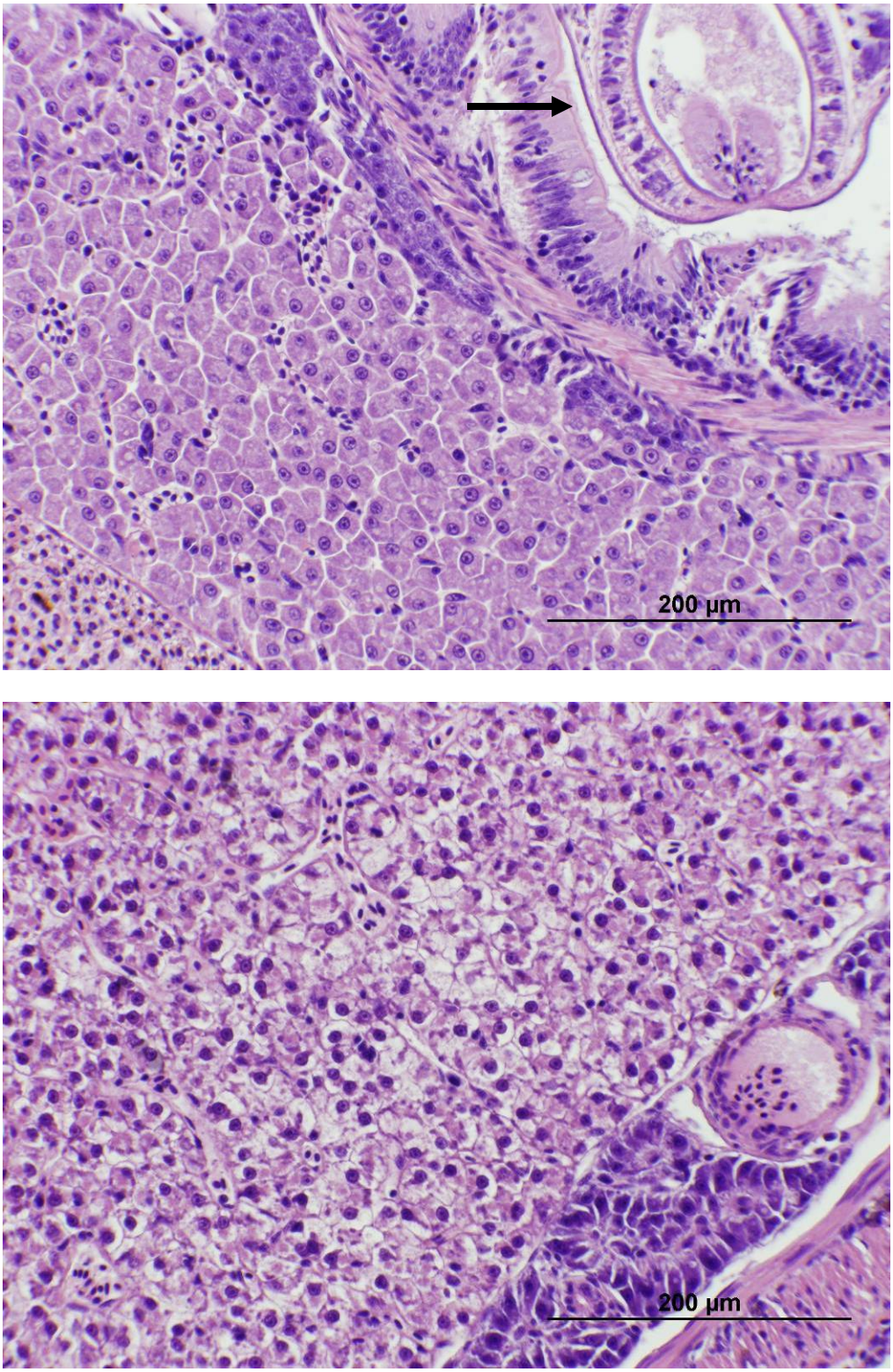

Fathead minnow - A total 521 juvenile fathead minnows were examined between 14July and 9September. Length and weight remained similar in the energy assay sub-sample during August and September (Table 7). The wide range in length (27 – 60mm SL) observed in the 25August and 9September fish suggests that different spawning cohorts were migrating in Link River. Whole body triglyceride and protein levels tended to increase beginning with 27July sample and then remain level (Table 7). It is unclear why the 25August protein concentrations were significantly lower than 9September group. External signs of bacterial infection was low (<10%) in all collection groups (Table 8). Signs of trauma and de-scaling ranged from 0 -11% with the July groups having the higher prevalence of injury. *Lernaea* was seen in late August (12%) and September (1%) while the prevalence of blackspot (metacercaria) increased over time to 33% by 9September. A similar trend of increasing metacercarial cyst prevalence was seen in muscle sections (Table 9).

In gill sections, incidence of infection for *Trichodina* was 31% and 37% for *Myxobolus sp.* cysts (Table 9). *Myxobolus sp.* cysts were quite numerous in some individuals and may have impaired gill function (Fig.5) Another *Myxobolus* sp. was seen in the brain of a Fathead minnow captured on 27July (Fig.6). Epitheliocystis-like cysts were seen in gills from one fish in the 27July and 11August collections. Trematodes and cestodes, in either the intestine or peritoneal cavity, were observed in 14% of the samples (Fig. 4). Several specimens contained a cestode that filled the entire visceral cavity and could be *Ligula sp.* The incidence of trematode infection in the eye was 6%. Despite the high incidence of parasite infection, inflammatory cells within the peritoneum were seen in only 16% of the fish (Fig. 7). Rodlet cells surrounding the brain were first observed in Fathead minnows beginning 11August. A unique section of *Lernaea* and its holdfast within the muscle was observed in 9September specimen (Fig 8).

In kidney sections, two fathead minnows had presumptive *Chloromyxum sp.* spores within the tubules. They were not associated with any lesions. Hyaline droplets, within the proximate convoluted tubule epithelium, occurred in 16% of the fish and was associated with alkaline water periods (>pH 9.7). This condition is often associated with diuresis associated with alkalinity (Foott et al. 2009). One or two fish per collection had livers with eosinophilic inclusions within the hepatocytes (Fig 9). It is likely that the inclusions were protein droplets. There was no correlation between kidney hyaline droplets and the hepatocyte inclusions.

Table 7.
Fathead Minnow Standard length (SL, mm), weight (WT, 0.1g), Condition factor (KSL= Wt / SL^3*10^5), triglyceride (TG mg / g fish), and protein (PRO mg / g fish). Data from 12 fish per sample date recorded as mean (SEM) and range. . Letters in common indicate that the differences were not significant (P<0.05).

	14-15JUL	27-28JUL	11-12AUG	25-26AUG	9 SEP
SL	26 (1) bc 22 – 30	33 (1) b 29 - 35	35 (1) a 32 – 39	39 (2) a 27 – 49	36 (3) a 28 - 60
WT	0.27 (0.02) b 0.15 – 0.37	0.59 (0.04) a 0.42 – 0.83	0.66 (0.03) a 0.50 – 0.88	1.1 (0.11) a 0.37 – 1.74	0.80 (0.20) a 0.28 – 2.81
KSL	1.46 (0.05) b 1.2 – 1.8	1.68 (0.04) a 1.4 – 1.9	1.49 (0.04) b 1.3 – 1.7	1.71 (0.04) a 1.4 – 1.9	1.40 (0.06) b 1.2 – 1.9
TG	16.5 (2.0) b 7.9 – 29.3	26.7 (0.9) ab 20.7 – 34.2	28.2 (3.5) ab 11.4 – 50.5	32.5 (2.4) a 9.1 – 40.3	32.0 (2.4) a 21.9 – 45.8
PRO	52.9 (2.3) b 47.6 – 71.7	59.6 (1.9) ab 46.9 – 67.6	58.7 (5.4) ab 28.6 – 88.6	54.2 (2.4) b 39.4 – 69.4	68.0 (2.3) a 51.0 – 78.2

Table 8.
Fathead Minnow external observations (number of fish with sign, % of total no.examined, external signs at ≥ 10% highlighted in bold font). Total fish examined = N, moribund without external sign = MB, pale gill = PG, columnaris lesion = FC and number lesion imprints with filamentous gram-negative rods, petechial hemorrhages at fin base / skin = HM and number of d kidney imprints with gram-negative rods, Trauma = TR, ≥ 10% scale loss = DS, *Lernaea* attached = LR, metacercaria black spot = BS, lamprey wound = LP, missing eye = ME, short opercule = SO, abnormal spinal curvature = SC.

	14-15JUL	27-28JUL	11-12AUG	25-26AUG	9 SEP
N	109	109	101	92	110
MB	4 (3.7%)	0	4 (4.0%)	6 (6.5%)	1 (0.9%)
PG	1 (0.9%)	0	6 (5.9%)	3 (3.3%)	1 (0.9%)
FC F-GNR	1 (0.9%) 0 / 1	0	0	1 (1.1%) 0 / 1	0
HM GNR	1 (0.9%) 0 / 1	1 (0.9%) 0 / 1	4 (4.0%) nd	4 (4.3%) 2 / 4	6 (5.4%) 0 / 5
TR	4 (3.7%)	**12 (11.0%)**	0	2 (2.2%)	10 (9.1%)
DS	7 (6.4%)	10 (9.2%)	1 (1%)	1 (1.1%)	2 (1.8%)
LR	0	0	0	**11 (11.9%)**	1 (0.9%)
BS	4 (3.7%)	0	2 (1.9%)	**12 (13.0%)**	**36 (32.7%)**
LP	0	0	0	0	0
ME	0	0	0	0	0
SO	0	0	0	0	0
SC	5 (4.6%)	1 (0.9%)	0	0	0

Nd not done

Table 9.
Fathead minnow histological observations common to most collection groups. Data reported as number of tissues with condition or parasite / total tissues examined (%) and incidence of infection observed over all collection groups (Incidence). Not all tissues examined from each fish.

	Incidence		4-15JUL	27-28JUL	11-12AUG	25-26AUG	9 SEP
Gill *Trichodina*	**16 / 51 (31%)**		4 / 12 (33%)	6 / 10 (60%)	3 / 11 (27%)	1 / 10 (10%)	2 / 8 (25%)
Myxobolus sp. cyst	**19 / 51 (37%)**		3 / 12 (25%)	2 / 10 (20%)	5 / 11 (45%)	7 / 10 (70%)	2 / 8 (25%)
Muscle metacercaria (blackspot)	**12 / 50 (24%)**		3 / 12 (25%)	1 / 10 (10%)	3 / 11 (27%)	0 / 9 (0%)	5 / 8 (63%)
Eye Trematode	**3 / 49 (6%)**		0 / 12 (0%)	0 / 10 (0%)	1 / 11 (9%)	1 / 8 (13%)	1 / 8 (13%)
Intestine Helminth*	**7 / 50 (14%)**		1 / 12 (8%)	1 / 10 (10%)	4 / 11 (36%)	1 / 9 (11%)	0 / 8 (0%)
Kidney Hyaline inclusions	**7 / 45 (16%)**		0 / 12 (0%)	0 / 10 (0%)	3 / 7 (43%)	2 / 9 (22%)	2 / 7 29%)
Inflammation within peritoneum / adipose tissue	**8 / 50 (16%)**		0 / 12 (0%)	1 / 10 (10%)	3 / 11 (27%)	2 / 9 (22%)	2 / 8 (25%)

* Helminth include trematode, cestode, and nematode

Figure 5. *Myxobolus* cysts in Fathead minnow gills (low and high power)

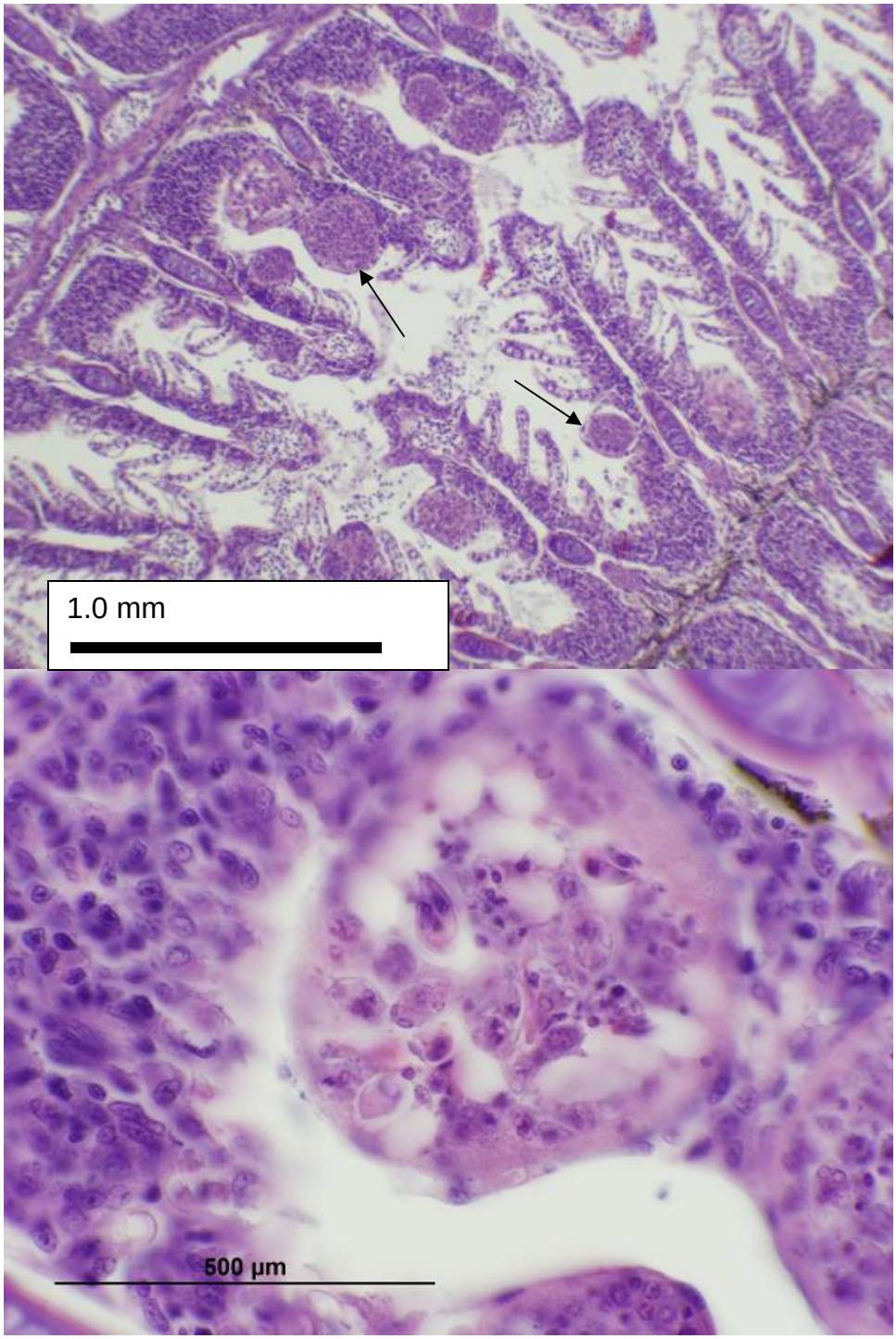

Figure 6. *Myxobolus* sp. cysts in Fathead minnow brain (low and high power).

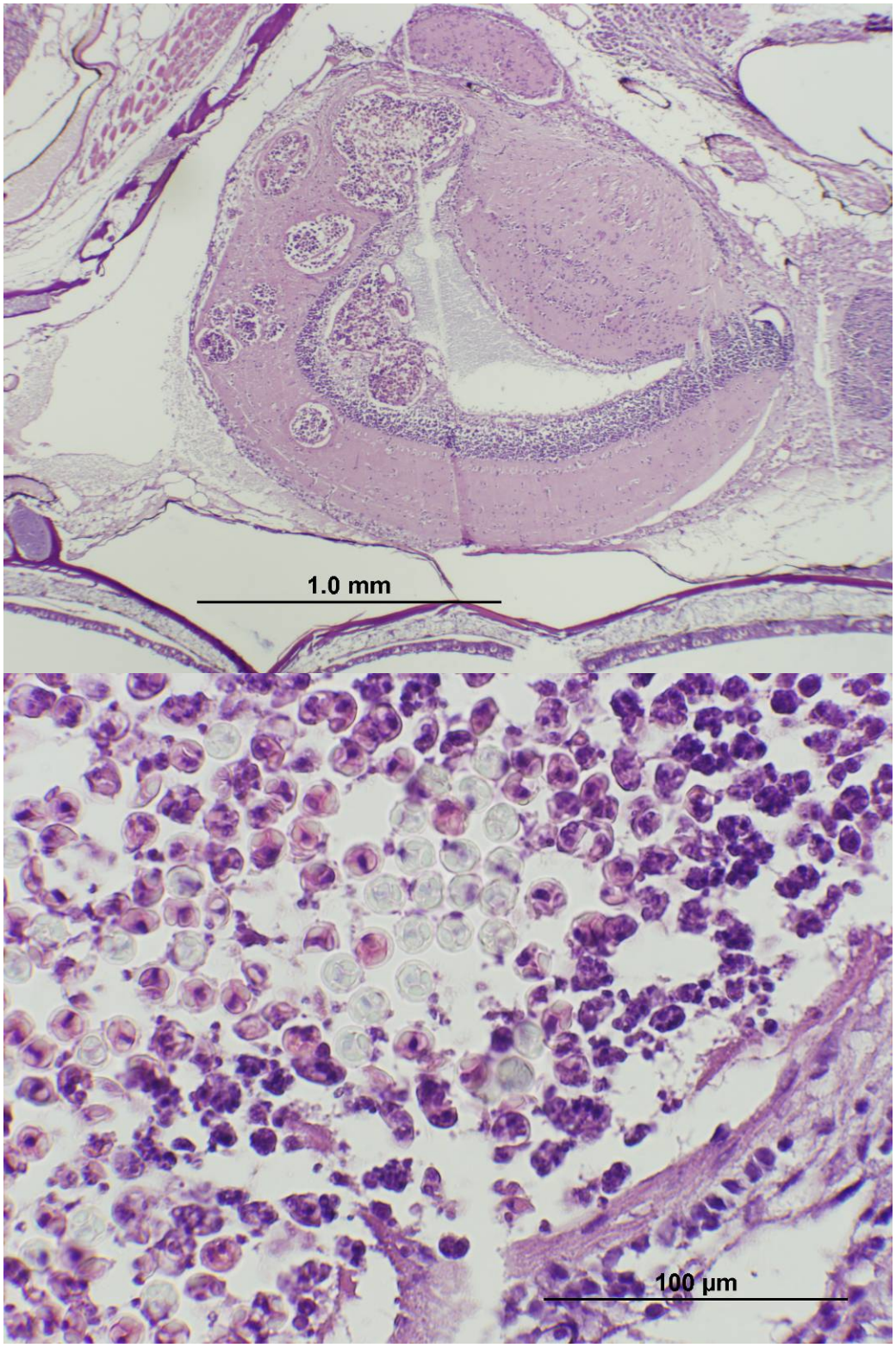

Figure 7. Inflammatory cells within Fathead minnow peritoneum. White arrow = rodlet cell, black arrow = eosinophilic granular cell, Oval = macrophages.

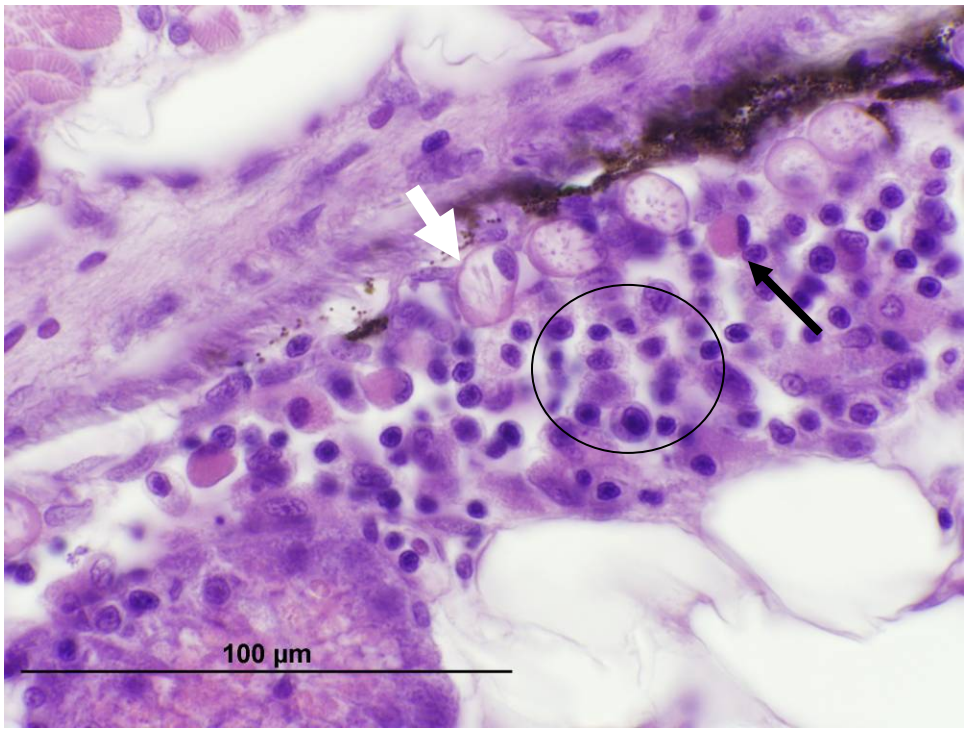

Figure 8. *Lernaea* attached to Fathead minnow skin and granulomatous response within the peritoneum to embedded holdfast (arrows).

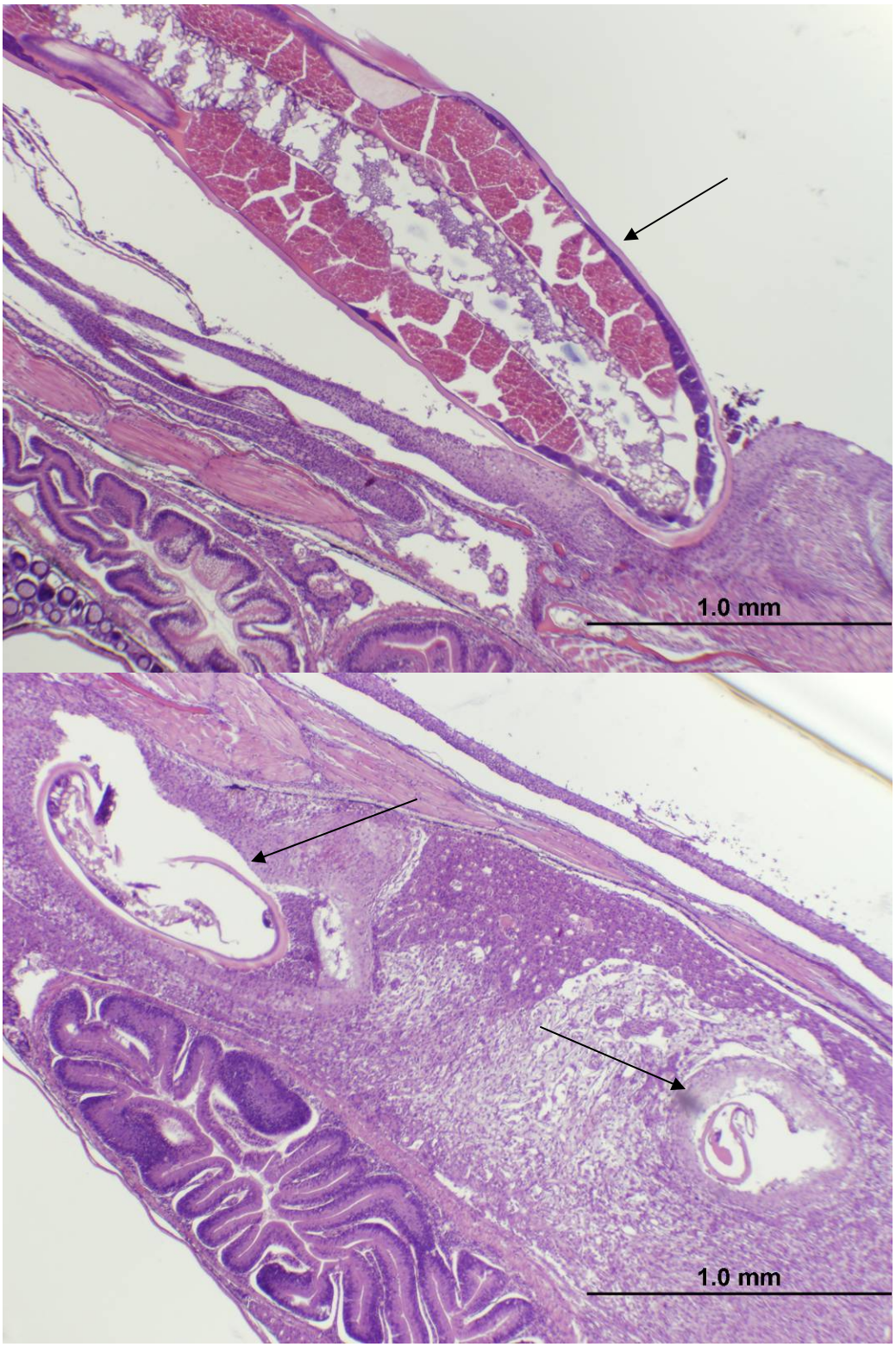

Figure 9. Fathead minnow liver heptocytes with eosinophilic inclusions (circles).

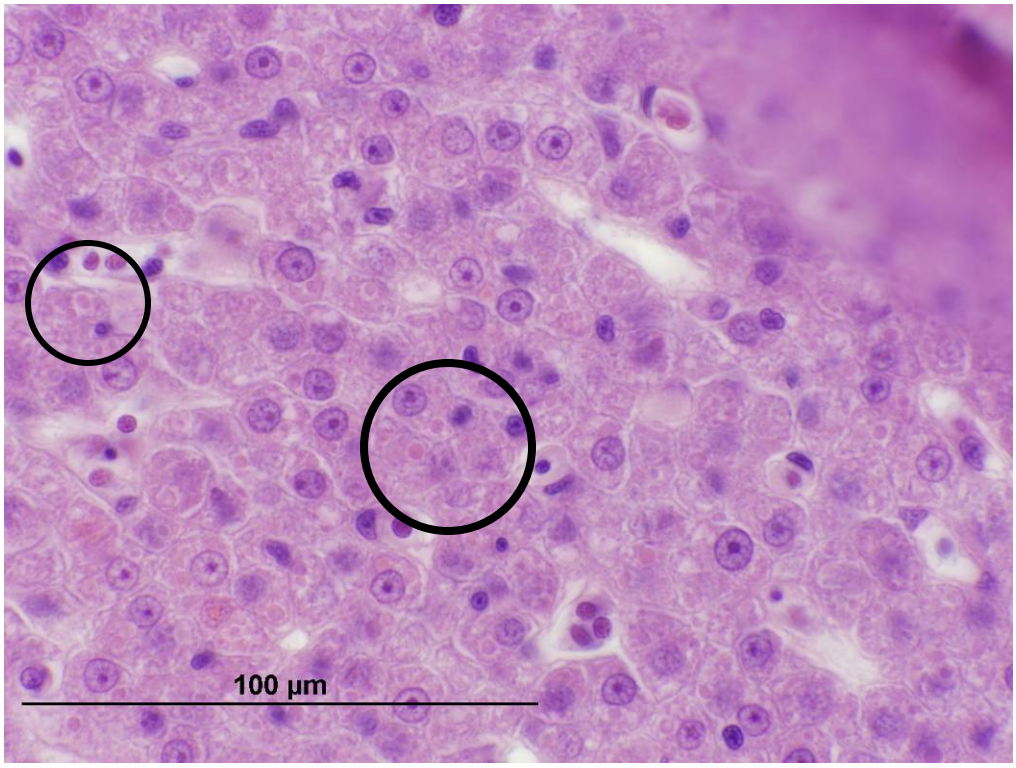

Chub-

A total 404 juvenile chubs were examined between 14July and 9September. Sample size was only 14 fish on 14July due to the difficulty of species identification at the 20-30 mm size. No histological samples were collected on 14July. Growth and energy stores appear to be static in the August and September collection groups. Both length and weight of the energy assay sub-sample remained similar after the 11August collection (Table 10). Whole body triglyceride and protein levels were variable among the collection groups and did not show a consistent increase over time (Table 11). External evaluation detected few (<10%) clinical signs of bacterial infection or trauma (Table 11). Encysted metacercaria (blackspot) was seen in 2 of the 5 collection groups at levels $\leq$ 8% and confirmed in histological sections. Attached *Lernaea* were only seen on 9September fish (24% prevalence).

Trichodina sp. was seen in 86% of gill sections and in lower numbers of olfactory pit sections (Table 12). Evaluation of gill epithelium could not be performed due to the variable fixation time of the sample set, however, in gill sections judged to be adequately fixed no hyperplasia was observed with *Trichodina* infestation. A low number of cysts containing basophilic granular material were seen in 19% of the gill sections and was presumptively identified as epitheliocystis infections (Fig 10). Novak and La Patra (2006) describe fish epitheliocystis as obligate, intracellular gram-negative bacteria in the order Chlamydiales. The bacteria induce hypertrophy of the infected epithelial cell however most infections tend to be benign.

One unique eye section contained a presumptive *Diplostomulum sp.* within the vitreous chamber (Fig. 11). A 46% incidence of helminth (trematode and cestode) infection of the intestine and peritoneum was observed in chubs. Little pathology was associated with the infections however significant number of inflammatory cells (Rodlet, macrophage, neutrophil, eosinophilic granular cells) were seen in the peritoneum from 92% of examined fish. Similar to Fathead minnows, rodlet cells were often seen around the brain (Fig 12). Pre-sporogonic myxosporeans within cysts were observed in 15% of the muscle sections. It is uncertain whether it is related to the same *Myxobolus* sp. seen in Fathead minnow gills. Only 9% of the kidney sections contained proximate convoluted tubules with obvious hyaline droplets in comparison to the 16% incidence seen in Fathead minnows. This finding suggests that chubs could readily acclimate to alkaline waters during the summer months.

Table 10.
Chub standard length (SL, mm), weight (WT, 0.1g), Condition factor (KSL= Wt / SL^3*10^5), triglyceride (TG mg / g fish), and protein (PRO mg / g fish). Data from 12 fish per sample date (14July = 5) recorded as mean (SEM) and range. Letters in common indicate that the differences were not significant (P<0.05).

	14-15JUL	27-28JUL	11-12AUG	25-26AUG	9 SEP
SL	26 (1) bc 22 - 30	32 (1) bd 30 - 36	41 (1) a 37 - 46	40 (1) a 31 - 46	43 (1) a 36 - 50
WT	0.29 (0.04) b 0.14 – 0.42	0.45 (0.03) b 0.32 – 0.70	0.97 (0.08) a 0.74 -1.74	0.95 (0.09) a 0.40 – 1.40	1.20 (0.13) a 0.56 – 1.87
KSL	1.62 (0.10) a 1.32 – 1.86	1.32 (0.05) b 1.13 – 1.78	1.40 (0.06) ab 1.12 – 1.79	1.41 (0.03) ab 1.22 – 1.60	1.43 (0.04)ab 1.16 – 1.59
TG	13.4 (1.5) ab 8.7 – 16.8	11.6 (1.2) b 5.9 – 17.5	22.6 (2.5) a 8.4 – 37.7	17.4 (2.0) ab 8.9 – 29.0	25.1 (2.6) a 8.3 – 35.3
PRO	57.4 (3.4) bc 50.2 – 69.8	67.9 (2.1) ab 57.1 – 83.3	45.5 (1.0) c 39.7 – 52.3	64.2 (2.0) a 55.2 – 77.5	63.2 (0.9) a 57.3 – 67.0

Table 11.
Chub external observations (number of fish with sign, % of total no.examined, external signs at ≥ 10% highlighted in bold font). Total fish examined = N, moribund without external sign = MB, pale gill = PG, columnaris lesion = FC and number lesion imprints with filamentous gram-negative rods, petechial hemorrhages at fin base / skin = HM and number of d kidney imprints with gram-negative rods, Trauma = TR, ≥ 10% scale loss = DS, *Lernaea* attached = LR, metacercaria black spot = BS, lamprey wound = LP, missing eye = ME, short opercule = SO, abnormal spinal curvature = SC.

	14-15JUL	27-28JUL	11-12AUG	25-26AUG	9 SEP
No.	14	105	100	123	62
MB	0	0	5 (5.0%)	2 (1.6%)	0
PG	0	0	0	2 (1.6%)	0
FC F-GNR	0	0	0	1 (0.8%) 0 / 1	0
HM GNR	0	0	0	1 (0.8%) 0 / 1	3 (4.8%) 1 / 3
TR	0	3 (2.8%)	0	3 (2.4%)	2 (3.2%)
DS	1 (7.1%)	4 (3.8%)	0	3 (2.4%)	3 (4.8%)
LR	0	0	0	0	**15 (24.2%)**
BS	0	2 (2.0)	0	10 (8.1%)	1 (1.6%)
LP	0	0	0	0	0
ME	0	0	0	0	0
SO	0	0	0	0	0
SC	0	0	0	0	0

Nd not done

Table 12.
Chub histological observations common to most collection groups. No fish were collected for histology on 14July. Data reported as number of tissues with condition or parasite / total tissues examined (%) and incidence of infection observed over all collection groups (Incidence). Not all tissues examined from each fish

	Incidence	27-28JUL	11-12AUG	25-26AUG	9 SEP
Gill					
Trichodina	**32 / 37 (86%)**	10 / 10 (100%)	9 / 9 (100%)	8 / 10 (80%)	6 / 8 (75%)
Myxobolus sp. cyst	**2 / 37 (5%)**	0 / 10 (0%)	0 / 9 (0%)	1/ 10 (10%)	1 / 8 (13%)
Epitheliocystis	**7 / 37 (19%)**	1 / 10 (10%)	2 / 9 (22%)	4 / 10 (40%)	0 / 8 (0%)
Muscle					
metacercaria (blackspot)	**6 / 34 (18%)**	0 / 10 (0%)	0 / 9 (0%)	0 / 7 (0%)	6 / 8 (75%)
Myxosporean cyst	**5 / 34 (15%)**	3 / 10 (30%)	1 / 9 (11%)	0 / 7 (0%)	1 / 8 (13%)
Eye					
Trematode	**1 / 33 (3%)**	0 / 9 (0%)	1 / 9 (11%)	0 / 7 (0%)	0 / 8 (0%)
Intestine					
Helminth*	**17 / 37 (46%)**	5 / 10 (50%)	2 / 9 (22%)	7 / 10 (70%)	3 / 8 (38%)
Kidney					
Hyaline inclusions	**3 / 32 (9%)**	0 / 8 (0%)	1 / 7 (14%)	0 / 10 (0%)	2 / 7 (29%)
Inflammation within peritoneum / adipose tissue	**33 / 36 (92%)**	10 / 10 (100%)	9 / 9 (100%)	8 / 9 (89%)	6 / 8 (75%)

* Helminth include trematode, cestode, and nematode

Figure 10. Presumptive Epitheliocystis inclusions in Chub gill.

Figure 11. Trematode (presumptive *Diplostomulum sp.)* within vitreous chamber of chub eye.

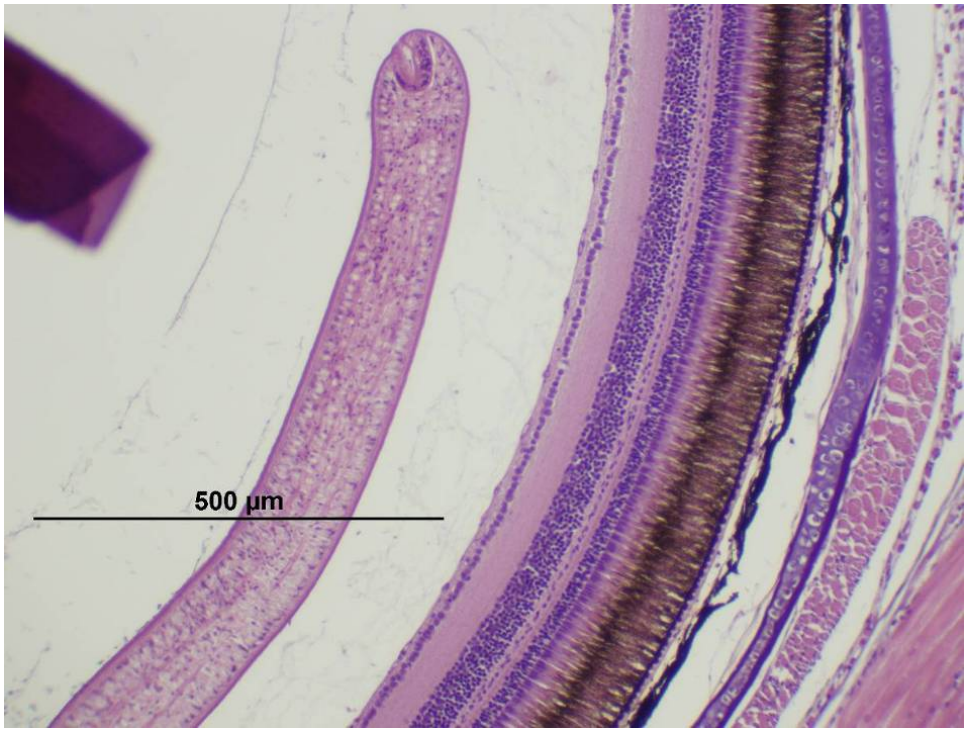

Figure 12. Rodlet cells along dura mater of Chub brain.

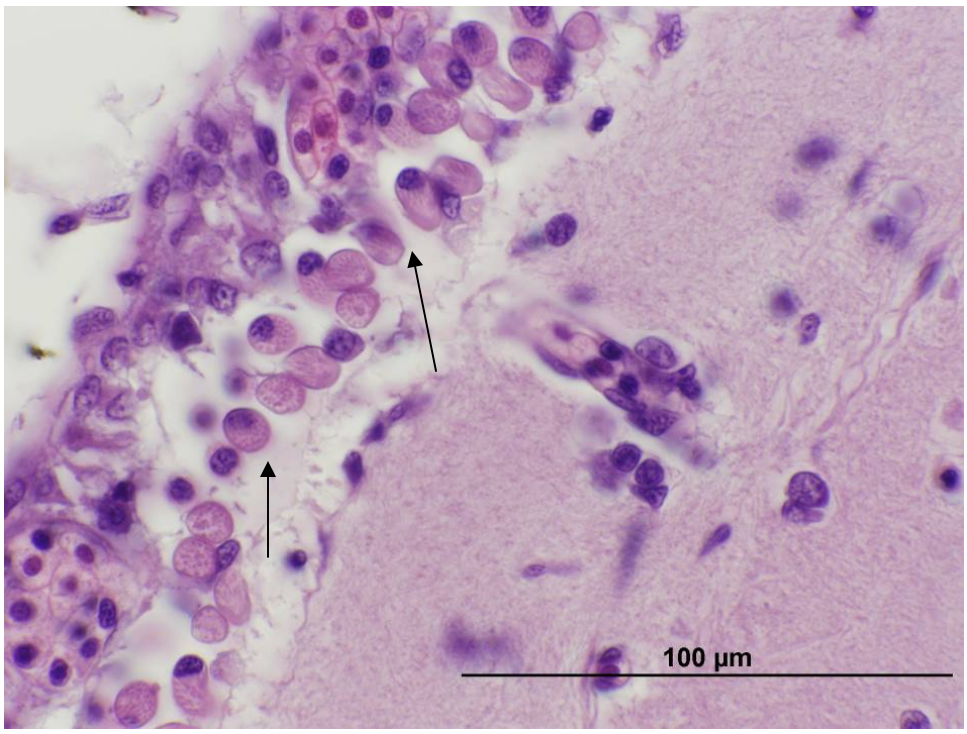

Discussion:
As in past studies, all sampled populations had high incidence of parasitic infection (Foott et al. 2005, 2007a and b).. In particular, several parasites (Trematodes, *Lernaea* copepod, myxozoans, and *Trichodina sp.*) are common to Upper Klamath Lake teleosts. Despite the high incidence of parasite infection, obvious disease (lesions, severe inflammation) was much less common in the examined fish. The presence of inflammatory cells within the peritoneum of all three Link River species indicates that these fish were responding to bacterial and parasitic infections throughout the summer. Given that relatively few suckers demonstrated clinical signs of disease, the role of infectious disease on juvenile sucker survival in the southern portion of Upper Klamath Lake is uncertain.

Trauma, due to the rotary screw trap operation, was a predominate observation in the Link R. juvenile suckers and would likely reduce post-capture survival (Wilkens 2010). The use of the rotary screw trap at Link R. (approximately 1700 cfs in July) is not a viable method for trap and haul. . Large numbers of salvaged juveniles (1000s) would be required to overcome post-release mortality rates. In order for salvaged juveniles to contribute to the Upper Klamath Lake adult population, an effective low-impact collection method is needed.

Low growth (increase in Standard length and weight) and static levels of whole body triglyceride was common to all three Link R. species during the summer. The high productivity of Upper Klamath Lake suggests that food is not a limiting factor.

Possible mechanisms of impaired growth and energy storage could be high energy demands related to impaired water quality (pH, ammonia) or reduced assimilation efficiency due to algal toxin interactions. The degree of capture bias at the Link R. trap is an unknown factor in extrapolating findings to the entire Upper Klamath Lake population (possibility that it is selective for smaller, weaker individuals). Overall health and fitness of the juvenile sucker population at both Link River and J-canal sites in 2009 appear to be sufficient for adequate survival in a trap and haul operation if a better capture method is employed.

Reference

Foott JS and R. Stone.2005. Bio-energetic and histological evaluation of juvenile (0+) sucker fry from Upper Klamath Lake collected in August and September 2004. U.S. Fish & Wildlife Service California – Nevada Fish Health Center, Anderson, CA. http://www.fws.gov/canvfhc/reports

Foott JS, R. Stone and R Fogerty. 2007a. FY2007 Investigational Report: Lack of disease response in juvenile Upper Klamath Lake suckers (age 0+) to adverse water quality conditions- Pilot study August 2007. U.S. Fish & Wildlife Service California – Nevada Fish Health Center, Anderson, CA. http://www.fws.gov/canvfhc/reports

Foott JS, R. Stone and E. Wiseman. 2007b. FY2006 Investigational Report: Energetic profiles and mortality response to winter starvation in juvenile suckers (age 0+) from Upper Klamath Lake in 2005. U.S. Fish & Wildlife Service California – Nevada Fish Health Center, Anderson, CA. http://www.fws.gov/canvfhc/reports

Foott JS, R. Stone, and R. Fogerty. 2009. FY2006 Technical Report: Effects of simulated algal bloom pH on juvenile Lost River Sucker energetics and growth. U.S. Fish & Wildlife Service California – Nevada Fish Health Center, Anderson, CA. http://www.fws.gov/canvfhc/reports.asp

Marine KR and P Lappe. 2009. Link River Dam surface spill experiment: Evaluation of differential juvenile sucker downstream passage rates. North State Resouces final report to Bureau of Reclamation, Klamath Basin Area Office, Klamath Falls, Oregon.

Novak BF and SE LaPatra. 2006. Epitheliocystis in fish. Journal of Fish Diseases 29: 573-588.

Weber LP, PS Higgins, RI Carlson, and DM Janz. 2003. Development and validation of methods for measuring multiple biochemical indices of condition in juvenile fishes. Journal of Fish Biology 63:637 - 658.

Wilkens A. 2010. Klamath Project: Link River endangered sucker trap and haul efforts, 2009. US Bureau of Reclamation, Mid-Pacific Region, Klamath Basin Area Office, 6600 Washburn way, Klamath Falls, Oregon. 97603

Woo NYS, HA Bern and RS Nishioka. 1978. Changes in body composition associated with smoltification and premature transfer to seawater in coho salmon (*Oncorhynchus kisutch*) and king salmon (*O. tschawytscha*). Journal of Fish Biology 13: 421 – 428.