U.S. Fish and Wildlife Service
California-Nevada Fish Health Center
24411 Coleman Hatchery Road
Anderson, CA 96007

Upper Klamath Lake Juvenile Chub Pathogen Survey

Narrative Summary:
In contrast to previous years, we did not observe *Lernaea* infections on any sampled fish. As seen in 2017, FES chub fry had significantly higher prevalence of *Aeromonas* sp (gram-negative bacteria) infection than lake cohorts. Gross observation of black spot (presumptive *Bolbophorus* metacercaria) was significantly higher in lake samples than FES chubs on August 8. The majority of fry showed no obvious external abnormalities. Parasite prevalence in chub fry (helminth and *Myxobolus* sp.) ranged from 9 – 30%.

Sample Dates: August 1 and 8, 2018
Collection sites:
South lake (**lake**) near Pelican Marina (3-4 trap nets fished overnight, sample 8:30 – 11:00)
Fish Evaluation Station (**FES**, A-canal), 20:00 – 23:00 collections

Principal Investigator(s):
JS Foott (field sampling, histology examination, bacteriology, report)
Ken Nichols (virology)
Scott Freund (histology sample preparation, media)

Objectives:
1. Determine prevalence of infection (POI) for systemic *Aeromonas sp.* Infection (dominate bacteria in lake fish), parasites, and viral agents in 0+age chub (<70mm)
2. Compare sample groups from lake (near FES) to out-migrant fry collected at FES.

Background: Previous survey efforts, by the FHC and others, have identified a suite of warm-water fish pathogens in Upper Klamath Lake fishes that include bacteria (*Aeromonas* sp., *Flavobacterium columnare*) and parasites (see appendix 1). The role played by infectious disease in recruitment failure of lake suckers is unresolved and large scale survey of this population is not possible. Given their abundance and similarity in pathogen infection, age 0+ chub were surveyed to examine prevalence and severity of infection trends.

Method: Each capture group was poured through a 5mm grate (in bottom of tote) to exclude fish smaller than ~ 40mm and the first 20 – 30 age 0+ chubs (40 – 70mm) netted out and euthanized in an overdose of MS222. Chub fry included tui chub and blue chub not identified to species and approximately 10% of the FES sample groups included fathead minnow fry. Each fish was examined for

external parasites and abnormalities. Every other fish was sampled for bacteriology (1uL loop into kidney via peritoneal incision streaked onto Ampicillin Dextrin Agar [*Aeromonas sp.* produce a yellow colony on this media]) or histology (peritoneal incision, placed into Davidson's fixative for 48h, decalcified for 1h prior to standard paraffin processing for sagittal H&E slides) for a maximum of 10 fish per sample type from each capture group. Those fry sampled for bacteriology were also evaluated for obvious helminth (nematode, cestode, trematode) infection of the viscera. At each site, a minimum of 3 sample groups were collected per sample date. Five fish pools of viscera collected from remaining fish for viral assay (EPC & CHSE214 cell lines, 15°C). Histology sample numbers were reduced as there was a problem with infiltration during processing.

General comments: Between July 30 and August 8**,** water quality (DO, temperature, & pH) recorded at the USGS Rattlesnake point Sonde were normal for summer bloom conditions and did not exceed critical thresholds for suckers. In total from all sites and sample dates, 312 age 0+ chubs and three 0+ suckers (FES on August 8) were examined and/or sampled for tissues. Majority (≥70%) of fry at both sites showed no obvious external abnormalities. No viral cytopathic effect observed in tissue culture inoculated with 24 x 5-pool chub samples (n=120 fish). In contrast to previous years (on both chub and suckers), we did not observe *Lernaea* infections on any fish. Salvaged juvenile suckers transported to the Gone Fishing site in November did have *Lernaea* infections. No liver hepatocyte abnormality, indicative of toxicity, was observed in 50 liver sections. The ciliate *Trichodina* was observed in a majority of gill sections with no associated hyperplasia; and Ich (*Ichthyophthirius multifiliis)* was not detected

Chubs collected from the lake were larger than those at FES [Total length mean (SD) on August 1= Lake 52(5) and FES 47(6), August 8 = Lake 57(6) and FES 49 (7)]. Fisher exact test performed on prevalence of infection for *Aeromonas* sp showed that FES fish had significantly higher prevalence than lake cohorts on the same date (P=0.012 and 0.002 for the sample 2 dates). Additionally, only FES chub samples contained > 10 colonies indicative of "high level" infections. This observation of greater FES bacterial infection prevalence and severity also occurred in 2017. In contrast, gross observation of black spot (presumptive *Bolbophorus* metacercaria) was significantly higher (Chi-sq=3.88, P=0.049) in lake samples than FES chubs on August 8. Overall observed parasite prevalence (helminth and *Myxobolus* sp.) ranged from 9 – 30% in the chub fry (Table 1).

Table 1. Prevalence of infection for all 2018 samples.

	Total (+)	Total (n)	POI
Aeromonas sp.	29	92	32%
Ah > 10 colonies	10	29	34%
Blackspot gross obs	40	312	**13%**
Blackspot metc histo	9	50	**18%**
Internal helminth obs	9	104	**9%**
Internal helminth histo	14	47	**30%**
Eye *Diplostomum* histo	7	50	**14%**
Myxobolus cyst gill/intestine histo	6	50	**12%**

Table 2. Summary of chub health examinations collected August 1, 2018 in Upper Klamath lake and FES. Bacteriology notes: samples with > 10 yellow colonies (*Aeromonas* sp.) identified by Biolog system: *A. sobria, A. shuhert, and A. allosccharophila.* One non-yellow sample with >10 colonies = *Pseudomonas pleoglossicida.* Only 10 histological samples could be evaluated from both groups. Lake1 refers to suckers collected in net 1, Lake 2 refers to suckers collected in net 2, and Lake 3 refers so suckers collected in net 3. The time indicated after FES in FES20:30, FES21:30, and FES22:30 refer to the time of day that the net was pulled and that fish were collected from at the FES (Fish Evaluation Station) at the A-canal head gates.

	lake1	lake1	lake2	lake2	lake 3	lake3	lake total	lake total	
	positive	*sample (N)*	*positive*	*sample (N)*	*positive*	*sample (N)*	*positive*	*sample (N)*	*POI*
Aeromona s sp.(yellow)							6	16	38%
Ah > 10 colonies							0	16	0%
non-yellow colonies							1	16	6%
Blackspot gross obs	0	22	3	26	4	26	7	74	9%
Blackspot metc histo							2	3	67%
Internal helminth obs	1	6	0	6	1	10	2	22	9%
Internal helminth histo							0	3	0%
Eye *Diplostomum* histo							1	3	33%
Myxobolus cyst gill/intestine histo							1	3	33%
Non-detections									
Lernaea cyprprinacaea	0	22	0	26	0	26	0	74	0%
F.columnaris lesion	0	22	0	26	0	26	0	74	0%
Histo gill ICH							0	3	0%
Histo gill Epitheliocystis							0	3	0%
Histo liver abnormality							0	3	0%

	FES20:30	FES20:30	FES21:30	FES21:30	FES22:30	FES22:30	FES total	FES total	
	positive	*sample (N)*	*positive*	*sample (N)*	*positive*	*sample (N)*	*positive*	*sample (N)*	*POI*
Aeromona s sp.(yellow)	9	10	4	6	2	2	15	18	83%
Ah > 10 colonies	6	9	0	6	2	2	8	17	47%
non-yellow colonies	5	10	1	6	0	2	6	18	33%
Blackspot gross obs	1	20	1	27	3	20	5	67	7%
Blackspot metc histo								7	0%
Internal helminth obs	1	10	1	10	0	2	2	22	9%
Internal helminth histo							3	7	43%
Eye *Diplostomum* histo							2	7	29%
Myxobolus cyst gill/intestine histo							1	7	14%
Non-detections									
Lernaea cyprprinacaea	0	20	0	27	0	20	0	67	0%
F.columnaris lesion	0	20	0	27	0	20	0	67	0%
Histo gill ICH							0	7	0%
Histo gill Epitheliocystis							0	7	0%
Histo liver abnormality							0	7	0%

Table 3. Summary of chub health examination collected August 8, 2018 from Upper Klamath Lake and FES (Fish Evaluation Station). Three suckers sampled at FES (64 – 70mm TL), *Aeromonas jandaei* detected in 1 of 2 bacterial samples. Gill *Trichodina* and kidney tubule myxozoan (presumptive *Parvicapsula*) seen in sucker histology samples (1 of 3 fish). Lake1 refers to suckers collected in net 1, Lake 2 refers to suckers collected in net 2, and Lake 3 refers so suckers collected in net 3. The time indicated after FES in FES20:30, FES21:30, and FES22:30 refer to the time of day that the net was pulled and that fish were collected from at the FES (Fish Evaluation Station) at the A-canal head gates.

	lake1	lake1	lake2	lake2	lake 3	lake3	lake total	lake total	
	positive	*sample (N)*	*positive*	*sample (N)*	*positive*	*sample (N)*	*positive*	*sample (N)*	*POI*
Aeromona s sp.(yellow)	0	10	0	10	0	10	0	30	0%
Ah > 10 colonies	0	10	0	10	0	10	0	30	0%
non-yellow colonies	1	10	3	10	0	10	4	30	13%
Blackspot gross obs	10	30	4	30	6	30	20	90	22%
Blackspot metc histo							3	16	19%
Internal helminth obs	1	10	2	10	1	10	4	30	13%
Internal helminth histo							3	16	19%
Eye *Diplostomum* histo							3	16	19%
Myxobolus cyst gill/intestine histo							2	16	13%
Non-detections									
Lernaea cyprprinacaea	0	30	0	30	0	30	0	90	0%
F.columnaris lesion	0	30	0	30	0	30	0	90	0%
Histo gill ICH							0	16	0%
Histo gill Epitheliocystis							0	16	0%
Histo liver abnormality							0	16	0%

	FES20:30	FES20:30	FES21:3(	FES21:30	FES22:30	FES22:30	FES total	FES total	
	positive	*sample (N)*	*positive*	*sample (N)*	*positive*	*sample (N)*	*positive*	*sample (N)*	*POI*
Aeromona s sp.(yellow)	1	10	2	10	5	8	8	28	29%
Ah > 10 colonies	0	10	0	10	2	8	2	28	7%
non-yellow colonies	2	10	4	10	1	8	7	28	25%
Blackspot gross obs	2	24	1	28	5	29	8	81	10%
Blackspot metc histo							3	24	13%
Internal helminth obs	0	10	0	10	1	10	1	30	3%
Internal helminth histo							8	21	38%
Eye *Diplostomum* histo							1	24	4%
Myxobolus cyst gill/intestine histo							2	24	8%
Non-detections									
Lernaea cyprprinacaea	0	24	0	28	0	29	0	81	0%
F.columnaris lesion	0	24	0	28	0	29	0	81	0%
Histo gill ICH							0	24	0%
Histo gill Epitheliocystis							0	24	0%
Histo liver abnormality							0	24	0%

Two of 20 chub kidney sections also with presumptive *Parvicapsula sp...* *A.veroni* identified in one chub bacterial sample that had > 20 yellow colonies.

Photographs/photomicrographs



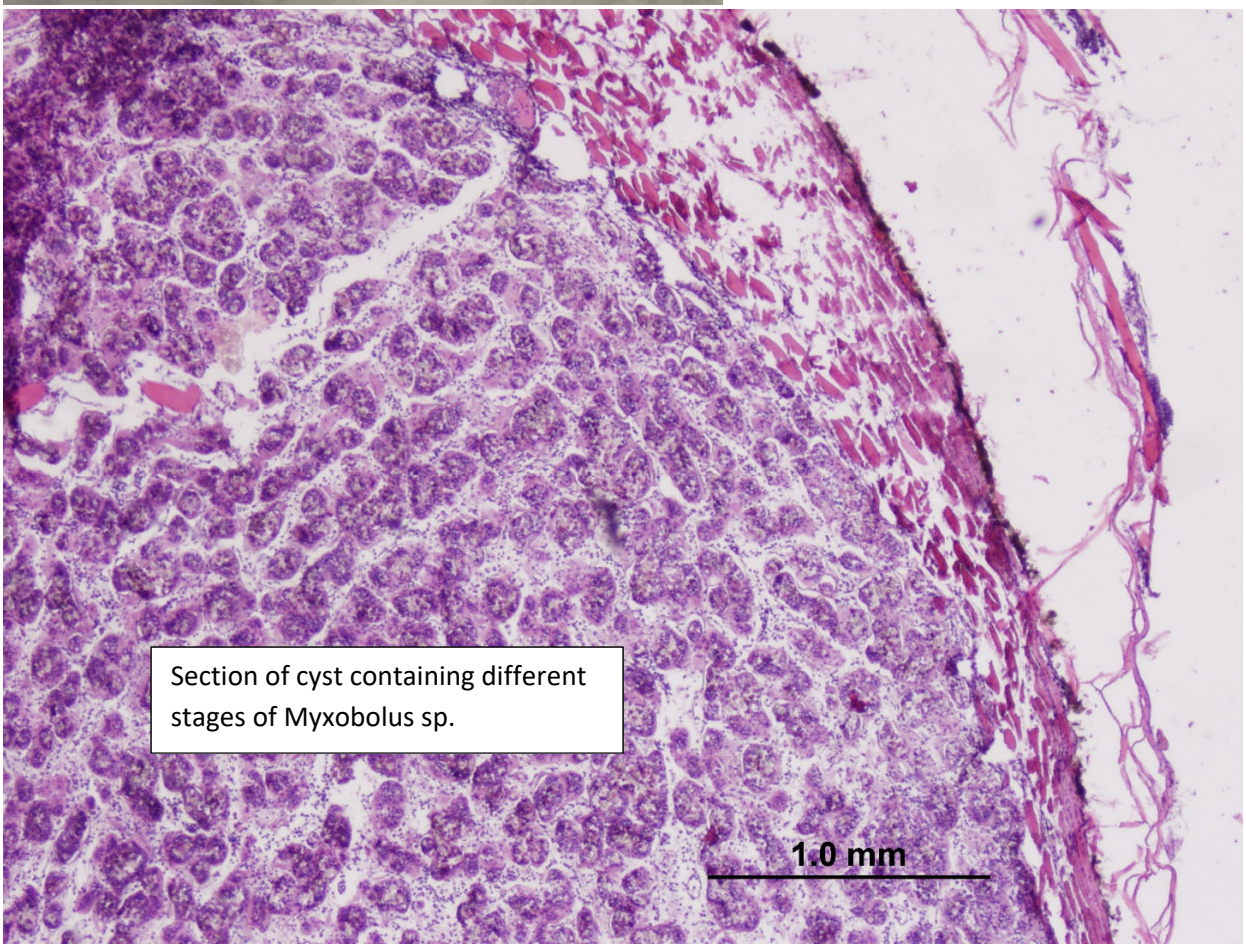

August 1 FES: Age 1+ chub with subdermal *Myxobolus* sp. cyst. Referred to as “lumpy” by attending biologists.

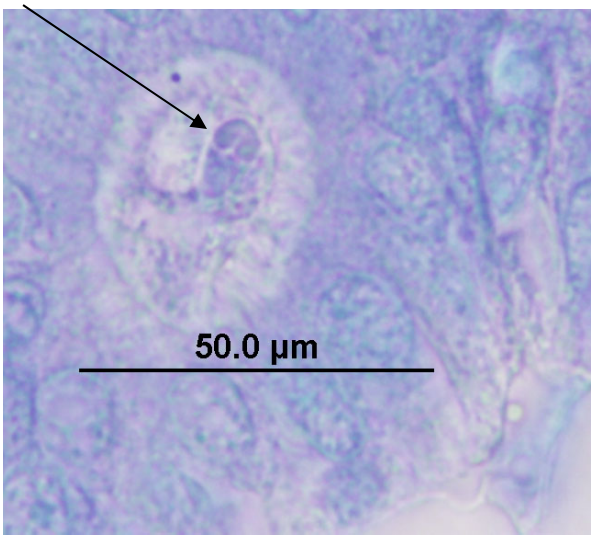

August 8 FES. Presumptive *Parvicapula* sp. myxospore within chub kidney tubule 1000x Giemsa stain. Arrow indicates polar capsules.

Partners: Acknowledge fish capture and permit assistance

Name	Agency
Danielle Hereford	USBR Klamath Basin Area Office
Brock Phillips	USBR Klamath Basin Area Office
James Ross	USBR Klamath Basin Area Office

Case Numbers: 18- 101 and 102 = August 1,

18-107 & 108 = August 8

Appendix: UKL macroparasites observed grossly or by histology

1. *Diplostomum scheuringi* – metaceraria found within vitreous chamber of eye, Body is more than twice as long as wide. Presumptive identification based on Mitchum DL 1995 Parasites of Fishes in Wyoming

2. Black spot trematode metacercaria stage in muscle *Bolbophorus* sp. Source: Janik et al. 2018.
3. Heart nematode; Contracaecum sp.
4. Cestode pleuroceroid stage in peritoneum: *Ligula intestinalis*
5. Copepo*d Lernaea cyprinacea*

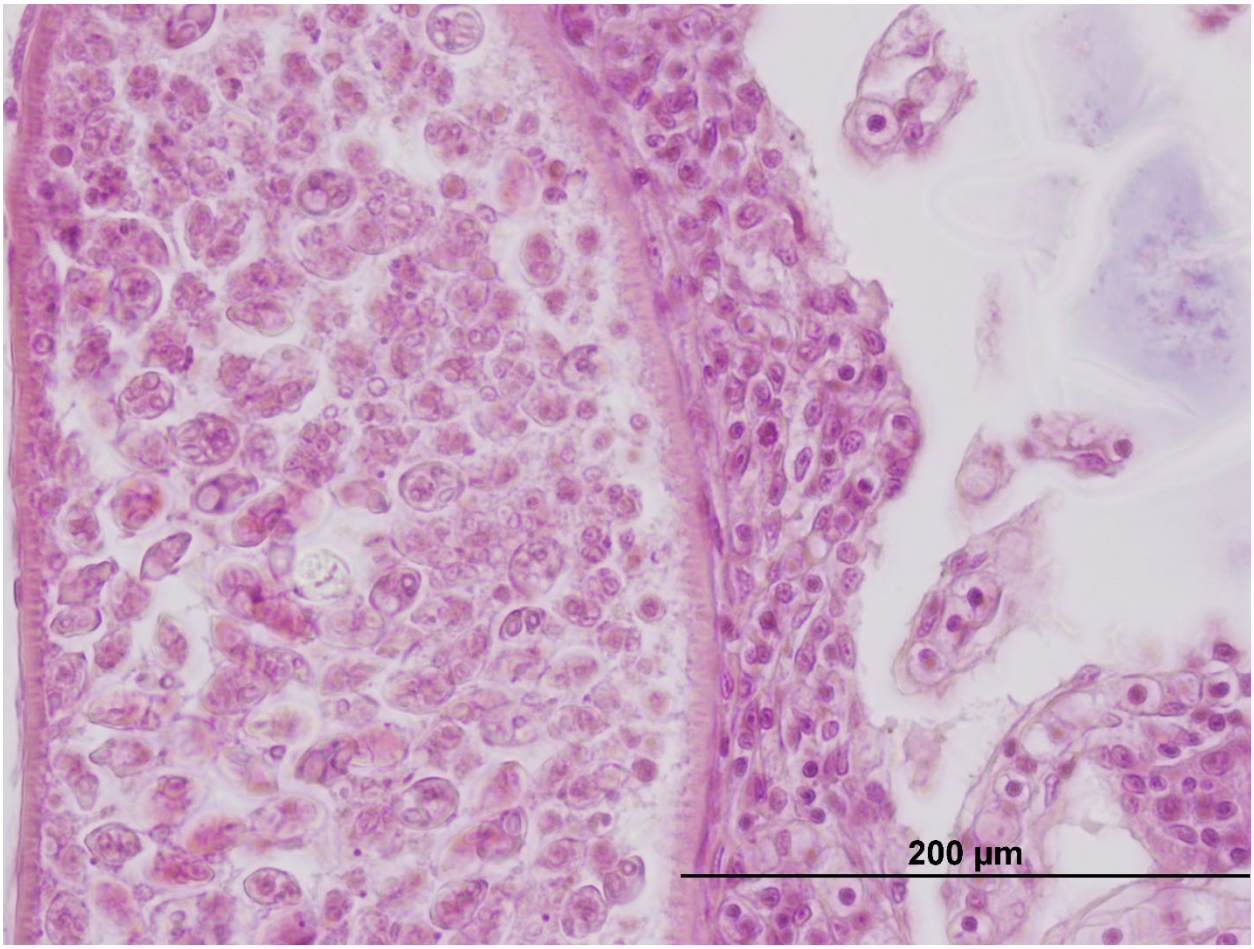
200 µm