UNITED STATES GOVERNMENT **FISH AND WILDLIFE SERVICE**

Memorandum

TO: Interested parties DATE: January 15, 2016

FROM: J. Scott Foott
CA-NV FHC, Anderson, CA

SUBJECT: Parasite infection of juvenile late fall and winter run Chinook in the Sacramento River: September – November 2015 observations in the Balls Ferry to Red Bluff reach.

Summary: Eighty juvenile Winter-run Chinook salmon (WCS) were collected at the Red Bluff Division Dam rotary screw trap between 15 Oct – 29 Nov. 2015 and sampled for histological examination. Early infections by *Ceratonova shasta* was observed in 15% of the sample set. External infections by *Ichthyophthirius multifiliis* were common in the first 6 weeks of collection. It is unlikely that parasitic disease was a major driver in the low egg to fry trend observed in 2015 however *Ceratonova shasta* infection could negatively impact the fry population during the later fall outmigration. Sentinel late-fall Chinook salmon, exposed to the Sacramento River for 5 days in late September at Balls Ferry and Red Bluff, later developed severe enteritis due to *C. shasta.* This observation indicates that this reach was highly infective at this time. A disease survey of the upper Sacramento River in the summer and autumn is warranted.

Background and Objectives: *Ceratonova (syn. Ceratomyxa) shasta and Parvicapsula minibicornis* are endemic myxozoan parasites of salmonid fishes and are associated with severe disease in natural Chinook salmon populations in the Pacific Northwest. *Ceratonova shasta* can cause hemorrhagic enteritis (intestinal tract) and *P. minibicornis* can induce glomerulonephritis (kidney). Both parasites have a complex life cycle involving a polychaete worm host as well as a salmon. Infections have been documented in Feather and Sacramento River juvenile Chinook salmon during the spring and in all adult salmon runs (1992 – present). Endangered Winter-run Chinook salmon (**WCS**) egg to fry estimates have markedly declined in the last several years. The USFWS California-Nevada Fish Health Center had no data on *C.shasta* infectivity in the Sacramento River coinciding with the temporal and spatial distribution of juvenile WCS. A pilot effort was conducted to determine the following:

- Infectivity of the river at Balls Ferry (~ rm 275) and Red Bluff Division dam (**RBDD**, rm 243) in late September (period of increased WCS migration past RBDD).
- Prevalence and severity of parasite infection in migrant WCS juveniles collected at RBDD from 15OCT – 29NOV.

Methods:

Sentinel salmon- On 21September, Coleman NFH juvenile Late-fall Chinook (**LFS**) were exposed for 5 days in sentinel cages held in the Sacramento River at Ball's Ferry (rm 275) and RBDD (rm 243). Fork length ranged from 90 – 160mm. After the exposure, fish were reared for 17d at the CANV FHC wetlab for a total of 22 days post-exposure (**dpe**). A control group of 10 salmon were also held in the CA-NV Fish Health Center wetlab. Water temperature during the exposure was 15 - 16°C (RBDD) and 18 - 19°C at the wetlab. A salmon diet was provided at 1% BW/d and mortalities were removed daily. Two to 5 fish per group were sampled at14 dpe and the remaining fish at 22 dpe. Select tissues (gill, kidney, intestine, and liver) were placed into Davidson's fixative and processed for histological examination.

WCS juveniles RBDD - On a weekly basis, 10 salmon were sampled from the RBDD rotary screw trap by USFWS Red Bluff FWO biologists between 15October – 29November 2015 (Section 10(a)(1)(a)= 1415-2M). Fork length was recorded, gill tissue fixed in RNAlater for gene expression analysis by Dr. Ken Jeffries (UC Davis),caudal fin fixed in ethanol for genetic archive, with the remaining carcass fixed in 10% buffered zinc formalin (Anatech Zfix). Prior to fixation the peritoneum was open to aid in fixative penetration. On 23November, the sample group was fixed with Davidson's fixative. Sagittal sections (fish < 40mm) or dissected tissues were processed for 5µm paraffin sections and stained with hematoxylin and eosin. Specimens were evaluated for parasite infection and tissue abnormalities.

Results and discussion:

Sentinel late fall chinook - A total of 23 and 26 fish were exposed at Balls Ferry and RBDD locations respectively. All sentinels survived the exposure. Columnaris (*Flavobacterium columnare*) infection of skin and gill were associated with early mortalities in the first 10dpe (Balls Ferry 7 / 23 (30%), RBDD 9 /26 (35%)). No histological samples were obtained from mortalities however all affected fish had signs of enteritis (hemorrhagic intestine). The source of the *F. columnare* infection is uncertain as the hatchery population had experienced columnaris throughout the summer.

Both exposure groups had a high prevalence of infection for both *Ceratonova shasta* (86% RBDD and 94% Balls Ferry) and *Parvicapsula minibicornis* (50% RBDD and 69% Balls Ferry) that progressed into a disease state (Fig. 1) by 22 dpe. It is likely that the prevalence of severe infection was higher as early columnaris mortalities were not examined by histology (due to post-mortem necrosis). The external ciliate parasite *Ichthyophthirius multifiliis* was observed on the gills of some sentinels held at RBDD however the infections were of low intensity and did not result in gill hyperplasia. No parasites were observed or mortality occurred in the non-exposure control salmon. This data indicates that the river was highly infectious for *C. shasta* at these locations and the conditions were likely to result in disease associated mortality (direct within 2 weeks of exposure or in-direct (predation due to weakness)).

Table1. Prevalence of infection (number positive / total sample (**%**)) for *C.shasta* (CS1=early stage, minor disease, CS2= late stage, diseased), *P. minibicornis* (PM1=early stage, minor disease, PM2= late stage, diseased), and *Ichthyophthirius multifiliis* (GillIch) in non-exposed control (CON), and sentinel salmon exposed at Red Bluff Division Dam (RBDD) and Balls Ferry (BF).

		CS1	CS2	PM1	PM2	GillIch
14dpe	CON	0 / 2	0 / 2	0 / 2	0 / 2	0 / 2
	RBDD	4 / 4 (**100**)	0 / 4	0 / 5	0 / 5	0 / 5
	BF	4 / 5 (**80**)	0 / 5	0 / 5	0 / 5	0 / 5
22dpe	CON	0 / 2	0 / 2	0 / 2	0 / 2	0 / 2
	RBDD	0 / 11	9 / 11 (**80**)	8 / 11 (**73**)	0 / 11	4 / 9 (**44**)
	BF	2 / 11 (**18**)	9 / 11 (**82**)	9 / 11 (**82**)	2 / 11 (**18**)	0 / 11

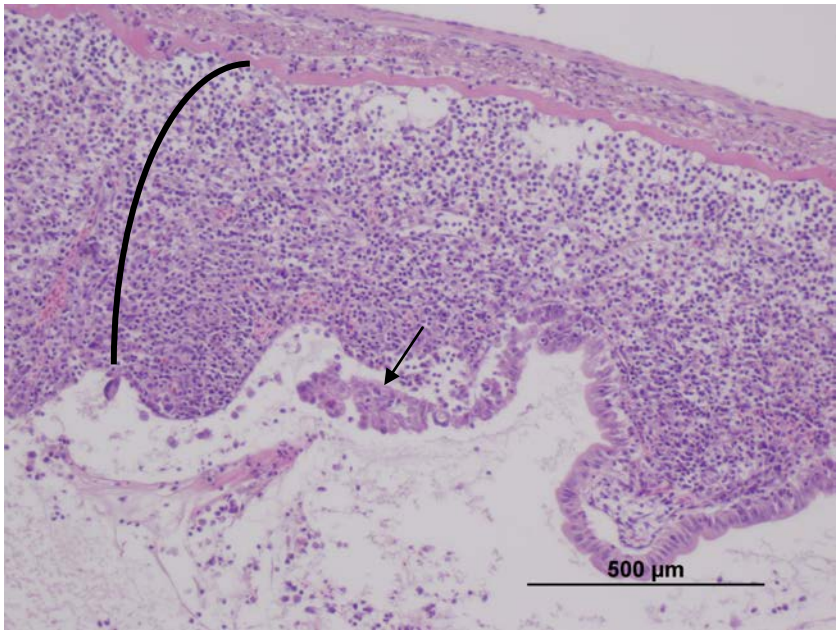

Figure 1. Sentinel salmon intestine showing enteritis due to *C.shasta* infection. Note inflammation of lamina propria (region highlighted by curved line) and erosion of epithelium (arrow).

WCS juveniles RBDD- Juvenile fork length ranged from 34 – 80 mm over the 8 week collection period (Fig. 2). Given this size range, it is apparent that the majority of salmon had reared for some period of time prior to capture. Prevalence of infection for *C.shasta* was 15% (12 of 80) and 81% (60 of 74) for *P. minibicornis.* Only one fish showed enteritits (CS2 rating 3-Nov) with the majority of *C.shasta* trophozoites being located in visceral adipose tissue blood vessels (Fig. 3). This observation suggests that infections were recent (within 10d of capture). Infection prevalence would likely be higher if the fish were assayed by the more sensitive PCR method. The high prevalence of *P. minibicornis* infection in the kidney glomeruli also suggests that *C.shasta* prevalence may be higher than 15% as this myxozoan parasite uses the same polychaete alternate host as *C.shasta.*

Glomerulonephritis (Fig. 4), due to *P. minibicornis* infection, became more prevalent in the late November samples (Table 2). This disease progression is likely a function of infectious dose and time post-infection. Skin infection by the ciliate *Ichthyophthirius multifiliis* (Ich) was seen in the majority of specimens collected between 15Oct and 19 Nov (Fig. 5). Trematodes (Fig. 6) were seen within the intestine of 5 specimens (6%) but were not associated with any lesions. No abnormalities were observed in specimens of gill (n=80), liver (n=79), or heart (n=30) tissue examined in the sample set.

Table 2. Prevalence of infection (number positive / total sample (%)) for *C.shasta* (CS1=early stage, minor disease, CS2= late stage, diseased) and *P. minibicornis* (PM1=early stage, minor disease, PM2= late stage, diseased) in juvenile Winter-run Chinook captured at RBDD between 15Oct – 29Nov.

	CS1	**CS2**	-	**PM1**	**PM2**
15-Oct	1 / 10 (**10**)	0 / 10		3 / 9 (**33**)	0 / 9
22-Oct	1 / 10 (**10**)	0 / 10		6 / 9 (**67**)	0 / 9
29-Oct	1 / 10 (**10**)	0 / 10		8 / 10 (**80**)	0 / 10
3-Nov	1 / 10 (**10**)	1 / 10 (**10**)		7 / 8 (**88**)	0 / 8
12-Nov	0 / 10	0 / 10		7 / 9 (**78**)	0 / 9
19-Nov	1 / 10 (**10**)	0 / 10		8 / 9 (**89**)	1 / 9 (**11**)
23-Nov	5 / 10 (**50**)	0 / 10		6 / 10 (**60**)	4 / 10 (**40**)
29-Nov	1 / 10 (**10**)	0 / 10		8 / 10 (**80**)	2 / 10 (**20**)
Cshasta	12 / 80 (**15**)				
Pminibicornis	60 / 74 (**81**)				

Figure 2. Fork length of juvenile Winter-run Chinook sample set. Ten fish per week were collected for disease analysis.

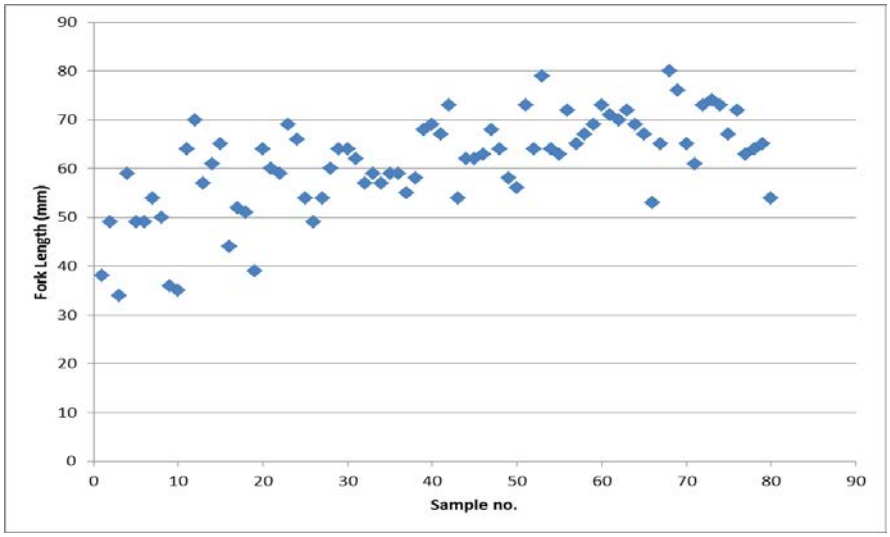

Figure 3. *C.shasta* trophozoite within visceral fat blood vessel (arrow) indicative of early stage infection. Note inflammation of surrounding adipose tissue.

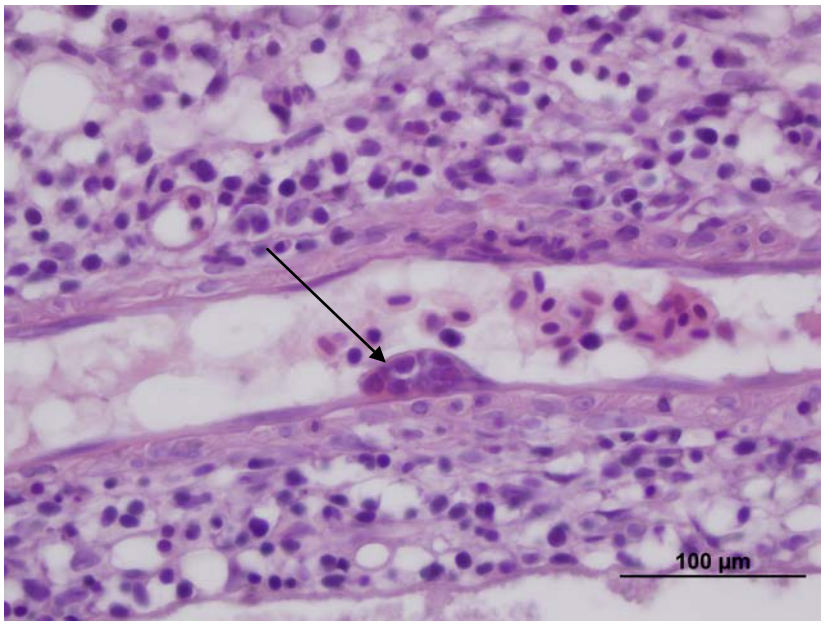

Figure 4. Glomerulonephritis (a) associated with *P. minibicornis* infection (arrow). A normal glomerulus within the kidney is shown in (b).

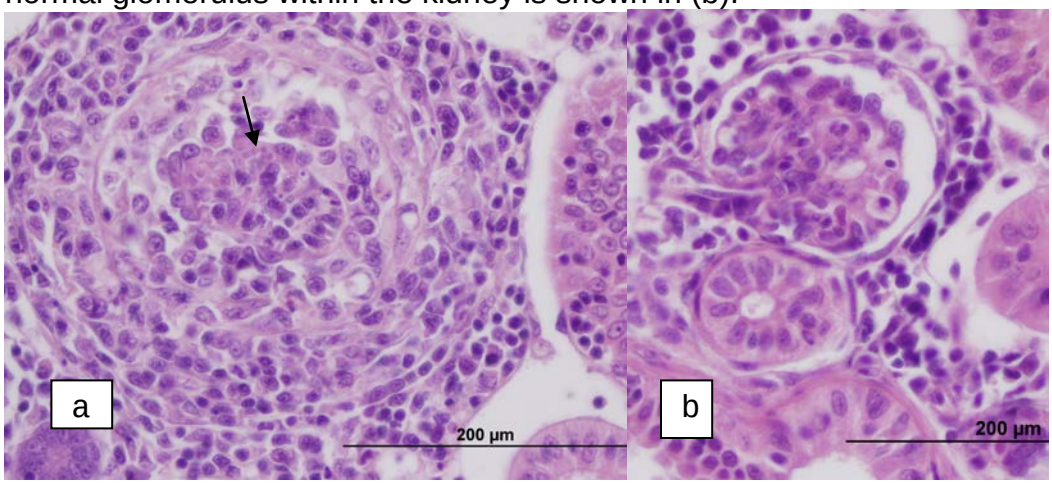

Figure 5. White spots (Ich) on fixed specimens (note on the head) and within buccal cavity (arrow).

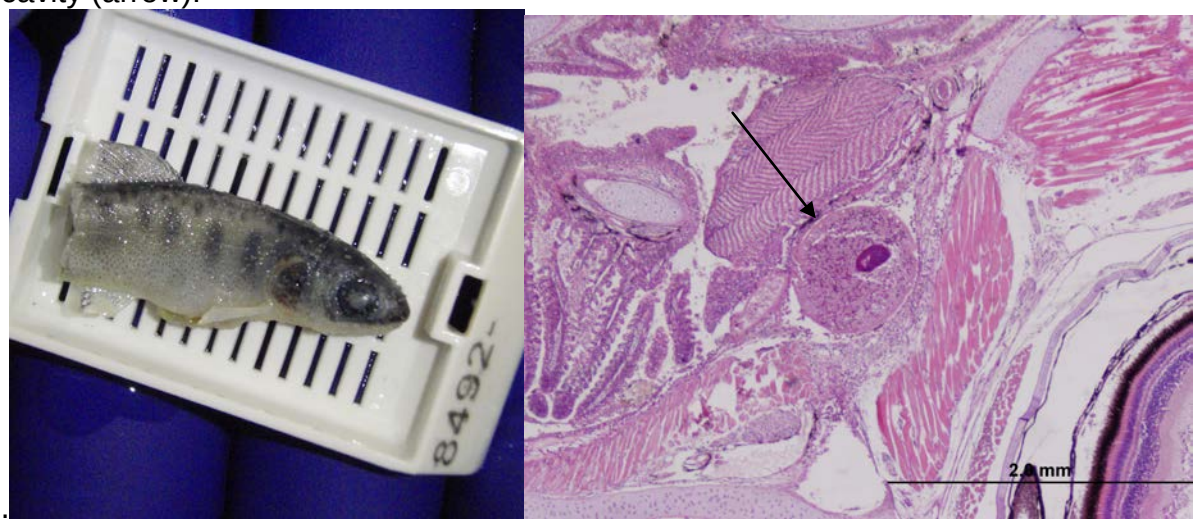

Figure 6. Trematodes within the pyloric ceca.

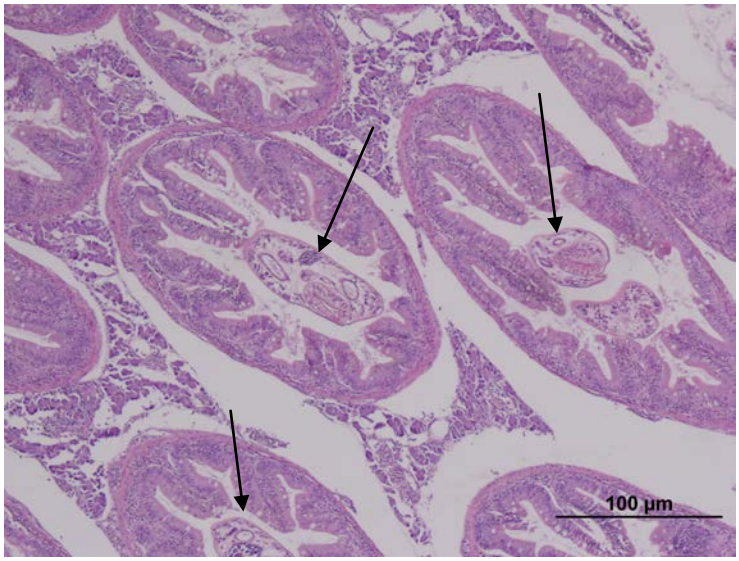

Conclusions:

- Sacramento River, at Balls Ferry and Red Bluff, was highly infectious for *Ceratonova shasta* in late September 2015. The level of infectivity was sufficient to cause disease and mortality in juvenile late fall Chinook sentinels exposed for 5 days.

- Prevalence of *C.shasta* infection (15%) was low in out-migrant WCS fry captured several weeks after the sentinel exposure (Oct15) through the end of November. These infections were largely at an early stage, indicating a recent exposure to the parasite. Fry had reared for weeks in locations with little to no *C.shasta* infectivity.
    - These observations **do not** support a significant role for *C.shasta* infection in the low egg to fry estimates generated from the RBDD trap data in 2015.
    - Disease **could impair survival of out-migrant** WCS fry in 2015 as;
        - *C.shasta* is a progressive disease and the early stage infections could go to a disease state over time.
        - Actual prevalence of *C.shasta* infection was likely higher than observed by histology. The high prevalence of *Parvicapsula minibicornis* (81%) infection suggests a higher *C.shasta* actinospore exposure as these myxozoans both share the same polychaete worm host.

- The high prevalence of *Ichthyophthirius multifiliis* infection observed on the skin of WCS fry is an unknown stressor in this out-migrant population. Fish can recover from Ich infections and become immune to the ciliate protozoan.

- Infectious disease impacts to WCS fry can be evaluated in the future with a combination of natural fry sampling, *C.shasta* DNA analysis of water, and sentinel exposures in the upper Sacramento River.