FY98 Investigational Report :

Health Evaluation of Adult Carp (*Cyprinus carpio)* from Lake Mead and Lake Mohave.

J. Scott Foott * and Rick Harmon
U.S. Fish & Wildlife Service
California- Nevada Fish Health Center
24411 Coleman Hatchery Road
Anderson, CA 96007
(530)365-4271 FAX 5303657150

July 1999

* direct correspondence

Summary: No significant viral, parasitic or bacterial pathogen infections were detected in the 47 carp sampled from Lake Mead (Hemenway Beach {7}, Las Vegas Wash {2}), Lower Colorado River (Willow Beach {20} and Lake Mohave (Cottonwood Cove {20}). Carp from the 4 sites were of similar size (group means ranged from 412 – 442 mm Total Length) and had good condition factors (group means ranged from 1.22 – 1.38 x 10^5). The male gonadosomatic index of the Willow Beach sample group (mean 2.3 %) was significantly lower than the other sites (means 6.5 and 5.4 %) which may be related to the effect of colder water temperatures on maturation. The Hemenway Beach group showed several different blood cell characteristics in comparison to the other sites. This group had both lower leukocrit values (% white blood cell vol.) and elevated eosinophil counts. Unfortunately, only 3 blood smears could be evaluated from the Hemenway Beach sample group. Plasma protein concentration and specific fraction amounts (electrophoretic separation) did not differ markedly between the sample groups. Histological examination of kidney, liver, and testes showed a common occurrence of multi-focal endogenous pigment deposits within apoptotic macrophages. The Hemenway Beach sample group tended to have a greater quantity of such pigments in the liver than the other sites. Special stains demonstrated that the pigments consisted of both ceroid , lipofuscin and hemosiderin. Ceroid and lipofuscin are often referred to as "age pigments" and form when cellular lipids and phospholipids are oxidized into an insoluble, intracellular pigment. It is the quantity and organ distribution that are probably of biomonitoring significance than their presence. Neoplastic foci were observed in 30% of the livers from Willow Beach group. Future studies should concentrate on the blood cell and histological lesion differences between site populations.

Introduction:

In May 1998, the California - Nevada Fish Health Center (**FHC**) assisted an inter-agency team (USFWS Nevada Fish & Wildlife Office, USGS National Water Quality Assessment program, Nevada Dept. of Wildlife) in a comparative study examining the effects of Las Vegas Wash water quality on the reproductive function and general health of adult common carp (*Cyprinus carpio).* Carp from two down-river locations were similarly examined for comparative purposes. The FHC performed three functions for the study: 1) organosomatic analysis and tissue sampling during field collection; 2) microbiological , hematological, and clinical chemistry assays , and 3) histological evaluation of select tissues. Other cooperators analyzed reproductive function indicators. Partial funding for supplies and technician time , totaling $4,500 was provided to the FHC (FY98 project code 1130- 11230-1F27).

Methods

Sexually mature common carp *(Cyprinus carpio*) were captured in shallow water by use of an electroshocking boat. Fish were collected from four general sites (Table 1).

Table 1. Sample sites.

Date	Site	No. of fish
18MAY98	**Hemenway Beach (HB)**, Lake Mead	7
18MAY98	**Las Vegas Wash (LV**), Lake Mead	2
	collection between 114 ° W 52' 50" and 114° W 53' 00"	
	36 ° N 07' 45" and 36° N 07' 55"	

19MAY98	**Willow Beach (WB),** Colorado R. above Lake Mohave collection between 114 ° W 40' and 114° W 42' 35 ° N 53' and 35° N 54'	21
20MAY98	**Cottonwood Cove (CC),** Lake Mohave collection between 114 ° W 41', 35 ° N 29' and 35 °N 30'	20

The fish were held alive in either an on-board tank or an in-situ livebox for 1 - 3 hours prior to necropsy. Each fish was lightly anesthetized with MS222 , struck on the head, rapidly examined for external abnormalities (gill, eye, skin), weighed, measured for total and fork length, and bled from the caudal peduncle with a heparinized syringe. One portion of the blood sample was used for the endocrine analysis (plasma vitellogenin, 11-ketotestosterone and 17β- estradiol). Another portion was used for a bloodsmear (methanol fixed, Leishman-Giemsa stain), measurement of hematocrit and leukocrit (microhematocrit tube centrifuged at 10,000 RPM, 10 min.), and collection of plasma. Blood smears were examined at 1000X magnification and the first 100 leukocytes counted as lymphocytes, thrombocytes (elongated forms only), neutrophils, eosinophils, or monocytes (Roberts 1989, Witten et al. 1998) . Clot activation during the collection of the blood sample can result in "spent" thrombocytes that resemble small lymphocytes (Roberts 1989). As these atypical thrombocytes are easily confused with small lymphocytes, a combined lymphocyte + thrombocyte count was compared with the granulocyte count (neutrophil, eosinophil, {monocytes were not included as they were rarely seen}).

Plasma was frozen on dry ice and later assayed for total protein (spectrophotometer assay using Pierce Chemical Co. BCA reagent and standard) and electrophoretic profile. Plasma protein electrophoresis was performed with a 7 FL sample run on a CIBA agarose gel (1M barbital buffer, 90V for 45 min.). The stained gels were scanned and the percent area of each fraction determined with Seprascan tm software. Analysis of Variance was performed on percent area values for each fraction (or combined fractions).

The peritoneal cavity was open and internal organs were examined for gross abnormalities. A sterile swab was inserted into the kidney and used to inoculate a trypicase soy agar plate. After the gonad was removed and weighed, the following samples were collected from each fish:

a) Kidney for *R. salmoninarum* antigen ELISA and viral assay on both Fathead minnow (FHM) and CHSE214 cell lines (five fish pooled samples cultured for 15 days at 15 °C).
b) Histological samples of kidney, liver, and gonad fixed in Davidson's fixative for 24 hours and transferred to 70 % ethanol. These tissues were processed for 5 μm paraffin sections and stained with hematoxylin & eosin. A subset of sections from each sample group were stained with Perl's Iron stain (hemosiderin), Acid fast stain (ceriod / lipofuscin), and Sudan Black B (ceriod / lipofuscin).

Three arbitrary categories were used to rate the quantity of apoptotic macrophages containing brown pigments in sections of liver, pancreatic tissue, and kidney:

normal	0 – 20 % of tissue
moderate	21 – 50 % of tissue
high	> 50 % of tissue

Results

Morphological data - Total length of carp from all 4 sites were similar and ranged from 412 – 442 mm (Table 2). Female weights and associated condition factors were larger than the males due to their gravid state. None of the sampled fish appeared emaciated and the majority were had visceral fat. Gonadosomatic index (GSI) values for ovulating females were likely in error due to the loss of eggs during capture and necropsy. The GSI for the ten WB male carp were significantly less than either the two HB males or the ten CC males (1-way ANOVA P=0.001). While surface temperatures at both WB and CC were 13 – 14 °C, it is possible that the WB fish experienced lower water temperatures that would retard sexual maturation. Capture stress were the probably cause of lens opacity seen in the eyes of several carp from each group as well as the large quantity of fluid (water?) in the lower intestines. No other significant abnormalities were observed during the external and internal gross examinations.

Table 2. Morphological data reported as mean (± S.E.M.) including Condition factor (Wt {gram}/ Total Length^3 {mm} x 10^5) and Gonadosomatic index (gonad wt / body wt x 100).

	Hemenway Beach	Willow Beach	Cotttonwood cove
Fork Length (mm)	412 (± 12)	442 (± 9)	413 (± 12)
Weight (g)	1405 (± 154)	1553 (± 97)	1269 (± 122)
Condition Factor			
Female	1.3981 (± 0.0506)	1.3278 (± 0.0436)	1.2464 (± 0.0273)
Male	1.3268 (± 0.1590)	1.2179 (+ 0.0347)	1.2002 (± 0.0296)
Combined Group	1.3777 (± 0.0506)	1.2578 (± 0.0280)	1.2233 (± 0.0203)
Gonadosomatic Index			
Female	14.8 (± 1.8)	9.0 (± 1.9)	11.8 (± 2.0)
Male	6.5 (± 0.6)	2.3 (+ 0.5)	5.4 (± 0.6)

Blood data – The blood cell indices of hematocrit (% packed RBC volume) and leukocrit (% packed white blood cell volume) were similar among the sample groups (Table 3). The above values were also within normal ranges of adult carp (Modra et al. 1998). While leukocrit values of the WB group were statistically greater (1-way ANOVA, P= 0.006) than the other 2 groups, the high variability observed in the data (coef. of variation 33 – 47 %) limits the diagnostic power of this measurement. Luskova (1997) reports similarly high variability in leukocrit values from another cyprinid fish (Chub*, Leuciscus cephalus).* Differential leukocyte counts from blood smears showed that the HB group may have been experiencing some stimulus for elevated granulocytes (Table 3). These HB samples had higher numbers of granulocytes (avg. 30 % ± 19) than either the WB or CC groups (both avg. 7 % ± 3). Unfortunately, only 3 blood smears could be evaluated from the HB group. Modra et al. 1998 reports similar lymphocyte : monocyte/granulocyte ratios in healthy 3 year old carp as was observed in

the WB and CC fish. The authors also discuss how acute stressors (NH_3, heavy metals, PCB) tend to result in decreases in lymphocyte and an inverse elevation of granulocytes in several species of fish. Chronic exposures had more variable results. Weyts et al. (1998) report that the stress hormone cortisol induces apoptosis (programmed cell death) in circulating B-cell lymphocytes of carp. No statistically significant difference was detected in the plasma protein values either between sample groups or sexes within a sample group (Table 3). Electrophoretic separation of the plasma protein fractions did not reveal any significant differences between the groups (Table 4).

Table 3. Blood data reported as mean (± S.E.M.) including hematocrit (% erythrocyte vol.), leukocrit (% white blood cell vol.), plasma total protein (g/dL), and leukocyte differential count from blood smears.

	Hemenway Beach	Willow Beach	Cottonwood Cove
Hematocrit	32 (± 3)	38 (± 2)	36 (± 2)
Leukocrit	0.4600 (± 0.0886) a	0.8445 (± 0.0655) b	0.6457 (± 0.0614) a
Plasma Protein			
Female	2.2 (± 0.1)	2.0 (± 0.1)	2.5 (± 0.3)
Male	2.3 (± 0.5)	1.9 (± 0.5)	2.4 (± 0.5)
Combined group	2.2 (± 0.2)	1.9 (± 0.3)	2.5 (± 0.3)
Differential Count	n= 3	n = 8	n = 8
% Lymphocyte and Thrombocytes	68 % (± 18) **	91 % (± 2)	93 % (± 3)
% Neutrophil, eosinophil	30 % (± 19) **	7 % (± 2)	7 % (± 3) ***

** Four of 7 Lake Mead carp blood smears unreadable due to clots. Females 4 and 6 had high percentage of eosinophils in smear (65 % and 24 % respectively).

*** Cottonwood cove female 7 with high number of neutrophils and eosinophils.

a-b Significant difference (1-way ANOVA, P=0.006).

Table 4. Plasma protein electrophoretic data reported as mean % area of band (± S.E.M.). Electrophoresis produced 6 protein bands (albumin + 5 globulin) from the adult carp sampled from Lake Mead / Hemenway Beach (HB, n= 6), Colorado River / Willow Beach (WB, n =8), and Lake Mohave / Cottonwood Cove (CC, n = 8).

	HB	WB	CC
Albumin	43.7 (± 2.6)	49.4 (± 1.7)	50.1 (± 1.9)
Globulin 1	12.0 (± 3.3)	9.6 (± 2.5)	6.7 (± 0.6)
Globulin 2+3	16.3 (± 0.8)	16.3 (± 1.0)	15.4 (± 0.7)
Globulin 4	12.8 (± 0.8)	12.6 (± 0.8)	12.8 (± 0.8)
Globulin 5	15.3 (± 1.9)	12.1 (± 2.2)	15.0 (± 2.8)
Albumin / Globulin ratio	0.990 (± 0.066)	1.230 (± 0.080)	1.200 (± 0.117)

Pathogen data – No obvious trend in bacterial or viral infections were detected between the sample groups. Various species of aquatic bacteria were cultured from between 14 - 50 % of a given sample group however, no obligate fish pathogens were isolated from any of the sampled carp (Table 5). The presence of so many common soil and water bacteria as well as the lack of clinical signs for bacterial infection suggest that some percentage of the bacterial isolations were due to surface contamination (water, intestinal tract contents, mucus).

Table 5. Bacterial isolates identified to general group and their prevalence of infection (number positive / total sample number {%}).

Hemenway Beach	1 / 7 (14 %)	*Micrococcus sp.*
Las Vegas Bay	1 / 2 (50%)	enteric
	{ either *Serratia, Citrobacter,* or *Enterobacter sp* by API profile **}	
Willow Beach	4 / 20 (20 %)	*Micrococcus sp.*
	1 / 20 (5%)	*Staphylococcus sp.*
	1 / 20 (5%)	*Bacillus sp.*
	1 / 20 (5%)	enteric (lost in passage prior to API tests)
	7 / 20 (35%)	
Cottonwood Cove	6 / 20 (30 %)	*Aeromonas* or *Pseudomonas sp.*
	2 / 20 (10 %)	enteric
	{ either *E.coli, Klebseilla sp.,* or *Citrobacter* by API profile **}	
	1 / 20 (5%)	*Bacillus sp.*
	1 / 20 (5 %)	*Micrococcus sp.*
	10 / 20 (50%)	

** API 20E biochemical test panels , bioMerieux.

No viral agents were detected in 9- five fish pooled samples (4 each from WB and CC, 1 from HB). Some samples from Hemenway Beach and Willow Beach were inadvertently

frozen during transport which could reduce viral recovery. Spores of a *Myxidium sp.* (Myxozoa) was seen in 3 of 20 kidney sections from the Willow Beach carp. There were no lesions associated with the spores. No other internal parasites were observed either grossly or by histology in any of the other sampled carp. A large number of the kidney samples produce strong signals in the polyclonal antibody ELISA for *Renibacterium salmoninarum* antigen (Table 6). This bacterium causes Bacterial Kidney Disease in salmonids and has not been described in cyprinids. Conformational tests using the Polymerase Chain Reaction (nested PCR, USGS-BRD primers) method on 10 high signal samples were negative for *Renibacterium salmoninarum.* These data suggest that the polyclonal anti-sera used in the ELISA cross-reacted with some component(s) in the carp kidney and thereby invalidates this *R. salmoninarum* screening method for carp.

Table 6. *Renibacterium salmoninarum* Enzyme Linked Immunosorbent Assay (ELISA) data reported as number positive / total sample number. Categories for the ELISA data are the following: BNC = below negative cutoff "negative", SUS = suspect level (Optical Density < 0.2 but above BNC), and POS = positive level (OD > 0.2).

Group	BNC	SUS	POS
Hemenway Beach + Las Vegas Bay	0 / 10	2 / 10	8 / 10*
Willow Beach	not done – all samples lost during processing		
Cottonwood Cove	0 / 20	1 / 20	19 / 20

*Five samples negative by nested PCR

Histological data – There were several observations common to most (>75%) of the kidney and liver (hepatopancreas) sections and their presence will be considered "normal" of these adult carp:

a. Golden-brown pigment deposits , often within apoptotic macrophage aggregates
b. Hyperplastic musculature surrounding the bile ducts
c. Thyroid follicles of various size within the kidney interstitium, usually < 50 / section
d. Calcium oxalate crystals in the distal kidney tubules from 26 – 47 % a given sample group

The extent of these changes may have some biomarker application. In particular, the distribution and concentration of endogenous pigments such as hemosiderin and lipopigments (lipofuscin and ceroid) were rated in the sections. Hemosiderin is a golden-brown pigment composed of ferritin micelles and occurs when there is excess iron in tissue (Cotran et al 1989). Prussian blue stain was used to differentiate this pigment from other endogenous pigments (Humason 1979). Hemosiderosis in fish is usually associated with either hemolytic anemia or excess dietary / environmental iron intake (Thiyagarajah et al.1998). Lipofuscin is an insoluble yellow-brown pigment and is often referred to as "aging pigment" (Cotran et al. 1989). It is composed of lipoprotein polymers formed when cellular polyunsaturated lipids are oxidized. Sudan black and acid fast stain were both used to differentiate lipochrome pigments such as lipofuscin from hemosiderin pigment (Carson 1991). Carson states that ceroid, another lipochrome pigment related to the peroxidation of cellular lipid, is positive for acid fast stain unlike lipofuscin. As both acid-fast positive and Sudan Black positive foci were

observed in the same brown pigmented sites, the term lipopigment will be used to describe the presence of either lipofuscin or ceroid. Melanin was also observed to a lesser degree in the sections however, it was distinguished from hemosiderin and lipofuscin by its darker black – brown granular appearance. Both hemosiderin and lipopigments were observed in the liver and kidney. Brown pigment foci within the testes were composed entirely of lipopigment. Hemosiderin was primarily seen in the liver and was often associated with apoptotic macrophage aggregates near acinar cells (carp liver contains cords of exocrine pancreatic tissue) and to a much lesser degree within the cytoplasm of hepatocytes. It was observed to occupy 10 – 20 % of the macrophage aggregates in the kidney interstitium with the remainder being lipopigment. The presence of hemosiderin within the liver was probably not reflective of a hemolytic condition as erythrocyte concentration was normal (estimated by hematocrit) and erythrocyte staining characteristics in the blood smears also appeared normal. The spleen is reported to be a major iron storage site in fish however, this organ was not examined in this study. The presence of hemosiderin could indicate excess iron uptake from the diet or environment (Thiyagarajah et al.1998). Its presence in carp collected at HB, WB, and CC suggests that it may represents a normal condition (the Las Vegas Bay site is not included as only 2 fish compose the histological sample).

The dominate brown pigment in the liver was determined to be lipopigment by Sudan black stains (Fig 1). Fine granular brown pigment was observed within the cytoplasm of hepatocytes in 30 % (6 /20) of the CC group and 29% (2 / 7) of the HB group. No such granular pigment distribution was seen in the WB carp. The HB fish tended to have greater quantities of brown pigment associated with the acinar cell and liver macrophage aggregates than either WB or CC groups (Fig 2 and 3). Similar ratings were given for the presence of brown pigment in the kidney sections from all 3 groups (68 – 74 % were rated as “high”). It is unclear what (if any) biological significance this semi-quantitative difference in brown pigment amount within the liver.

Neoplastic changes such as epidermal melanoma (sampled from two CC fish with dark raised patches on skin), presumptive cholangioma (Fig. 4), and basophilic “altered foci” in the liver were observed in both WB and CC fish (Table 7). Necrotic lesions were rarely observed in the kidney . These lesion included granulomatous cysts without obvious parasites and focal necrosis in the kidney interstitium (Table 7).

Table 7 Neoplastic changes and necrotic lesions observed in kidney and liver sections.

	HB	LV	WB	CC
Altered foci	0 / 7	0 / 2	4 / 18	5 / 20
Cholangioma	0 / 7	0 / 2	6 / 18	0 / 20
Kidney cysts	1 / 7	0 / 2	0 / 18	3 / 20
focal necrosis	0 / 7	0 / 2	1 / 18	1 / 20

fig 1

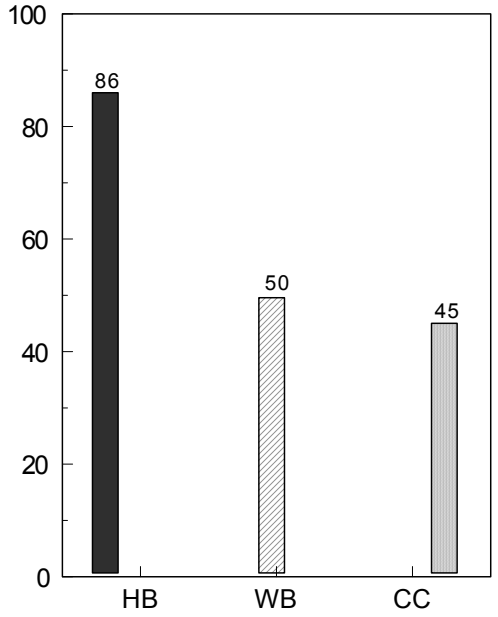

Fig. 2 Percentage of sections with acinar macrophage aggregates with brown pigment rated as high.

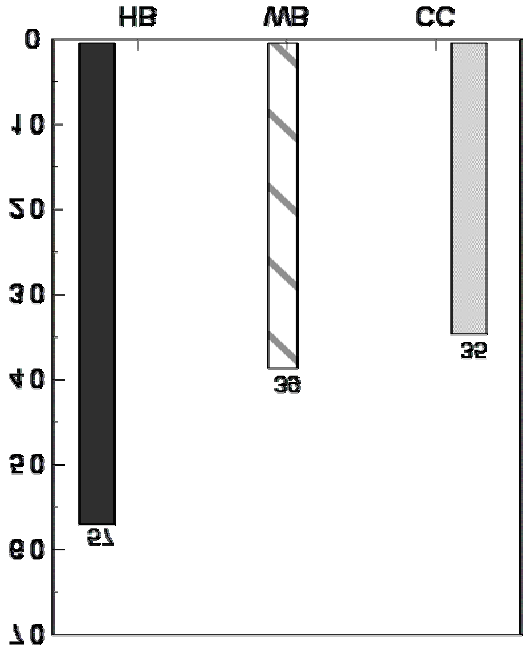

Fig. 3. Percentage of sections with liver macrophage aggregates with brown pigment rated as high.

fig 4

Discussion:
No obvious health differences were detected among the sample groups however, several histological and blood cell measurements suggest that the Lake Mead population (HB) was under stress. The presence of neoplastic changes in the livers from the downriver populations (WB and CC) prompts further study on the incidence and severity of such abnormalities in the carp population.

Acknowledgements:
We thank Kim True, Pat Collins, and Ken Nichols for their excellent technical assistance in the microbiological assays and electrophoresis work.

References:

Carson FL 1991. Histotechnology: A self-instructional text. ASCP Press, Chicago.

Cotran RS, V. Kumar and SL Robbins. 1989. Robbins Pathologic Basis of Disease. 4th ed., WB Saunders Co., Philadelphia.

Humason, G.L. 1979. Animal tissue techniques. 4th ed., W.H. Freeman and Co. , San Francisco, pg 470.

Luskova, V. 1997. Annual cycles and normal values of hematological parameters in fishes. Acta Sc. Nat. Brno, 31(5): 70 pp.

Modra H, Z. Svobodova, and J. Kolarova. 1998. Comparison of differential leukocyte counts in fish of economic and indicator importance. Acta Vet. Brno 67:215 – 226.

Roberts, RJ. (editor). 1989. Fish Pathology. 2nd ed., Bailliere Tindall, London.

Thiyagarajah A., WR Hartley and A. Abdelghani. 1998. Hepatic hemosiderosis in buffalo fish (*Ictiobus sp*). Mar. Environ. Res. 46(1-5): 203 – 207.

Weyts FAA, G. Flik , JHWM Rombout, and BML Verburg-van Kemenade. 1998. Cortisol induces apoptosis in activated B cells, not in other lymphoid cells of the common carp, *Cyprinus carpio* L. Dev. & Comp. Immunol. 22(5-6): 551 – 562.

Witten PE, W. Villwock, and L. Renwrantz. 1998. Haematogram of the tilapia *Oreochromis niloticus* (Cichlidae, Teleostei) and application of a putative phenoloxidase for differentiating between neutrophilic granulocytes and monocytes. Can. J. Zool. 76:310 – 319.

Attachments:
- Organosomatic data (4 sites)
- Histological data forms (kidney and liver)